

Examination of the Painful Wrist

Advanced Techniques for Therapists

Bushey Spire
26.11.2019

Mr Michael Elvey

Consultant Hand and Orthopaedic Surgeon

MBBS, BSc, FRCS (Tr & Orth), Br Dip Hand Surg (Gold medal)



Aims

- To provide a logical approach to the examination of a painful wrist
- Topography of the wrist
- Management principles of common conditions

History

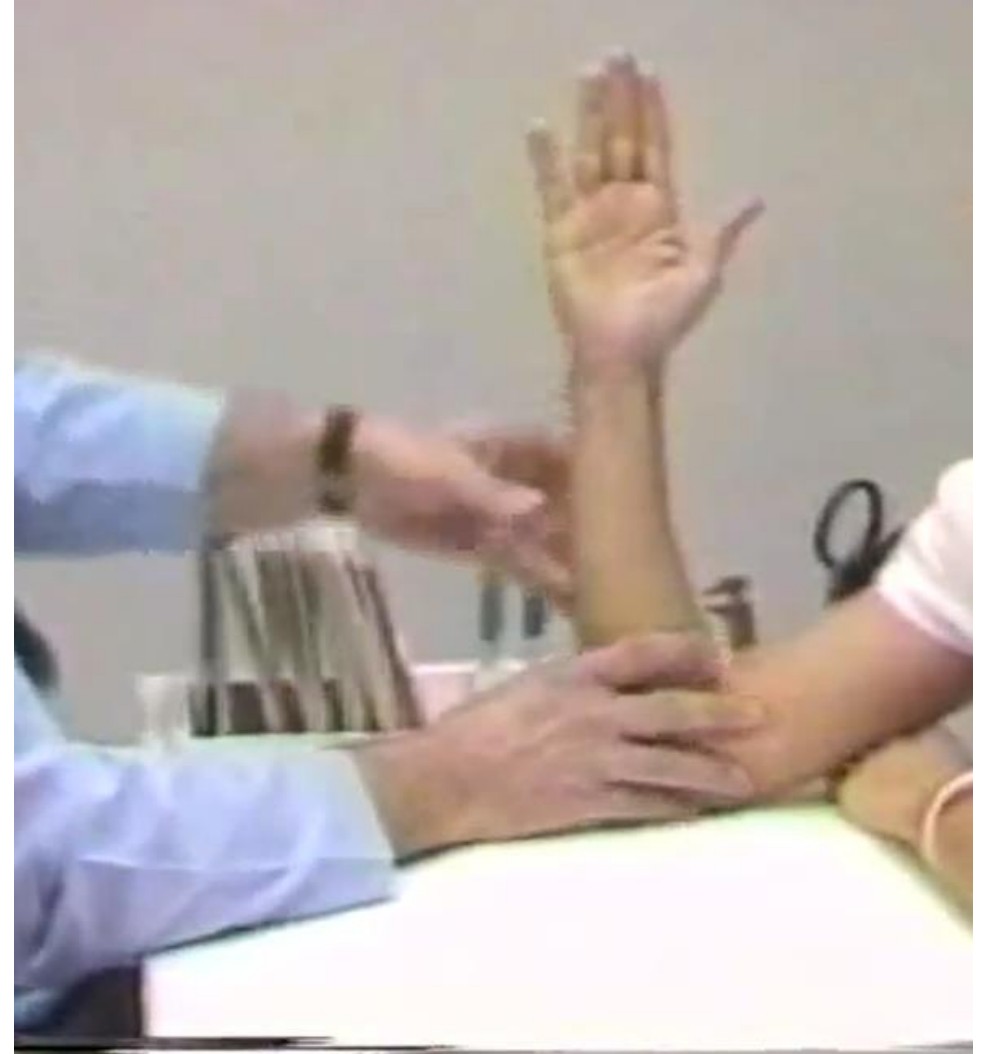- How did the symptoms begin
- WHAT are the symptoms
- WHERE are the symptoms felt
- WHEN do they experience the symptoms
- What are the resulting LIMITATIONS

Examination

- Common language
- Individualised
- Look – Move – Feel – Provocative manoeuvres

Set Up

- Remove all jewellery
- Table for resting hand / elbow
- Sit opposite with low table in between, elbow on table, fingers to ceiling



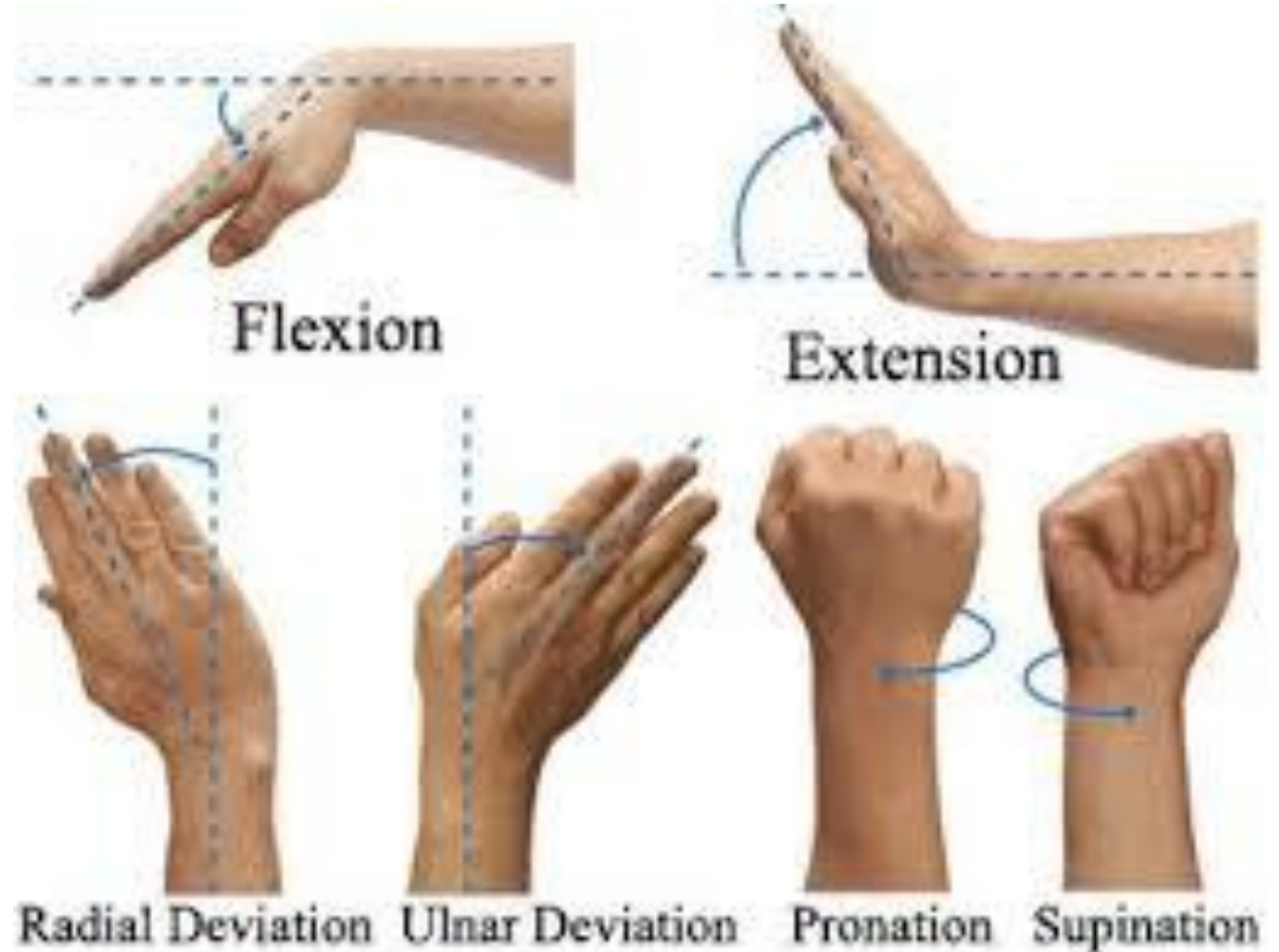
Inspection

- SWAB
- Creases, contours
- Posture
- Head-on view



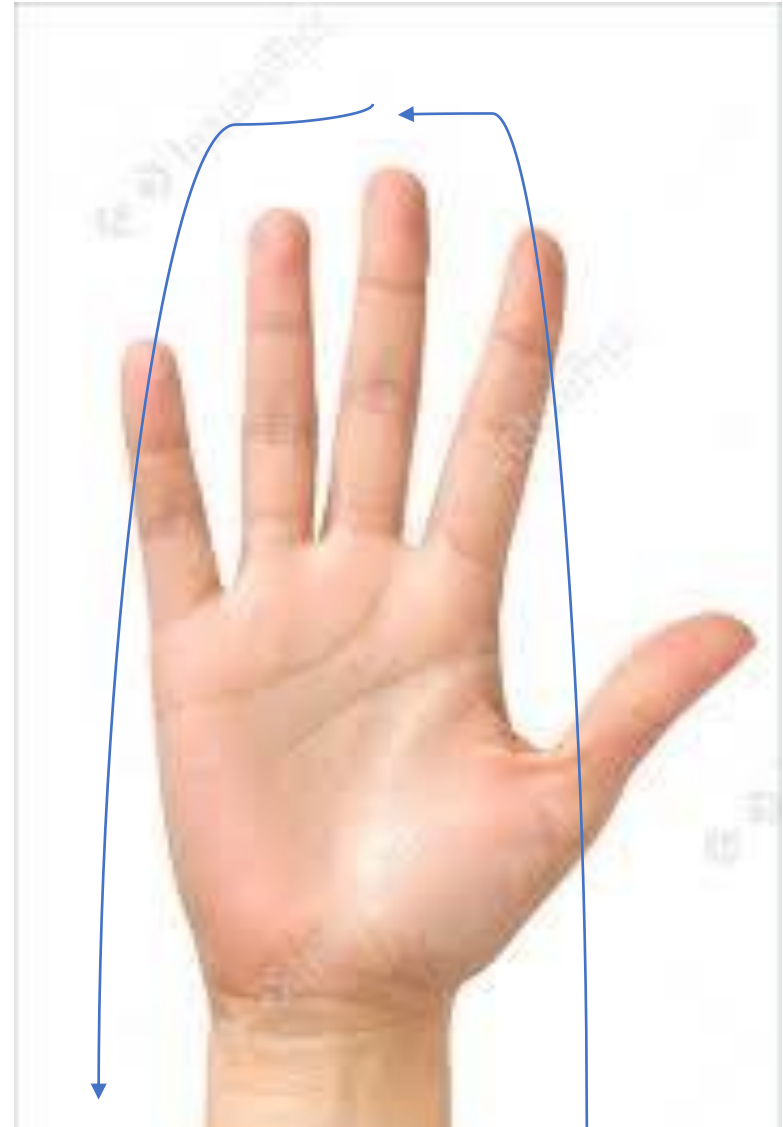
Movement

- Flexion / Extension
- Radio/Ulnar Deviation
- Pro/Supination



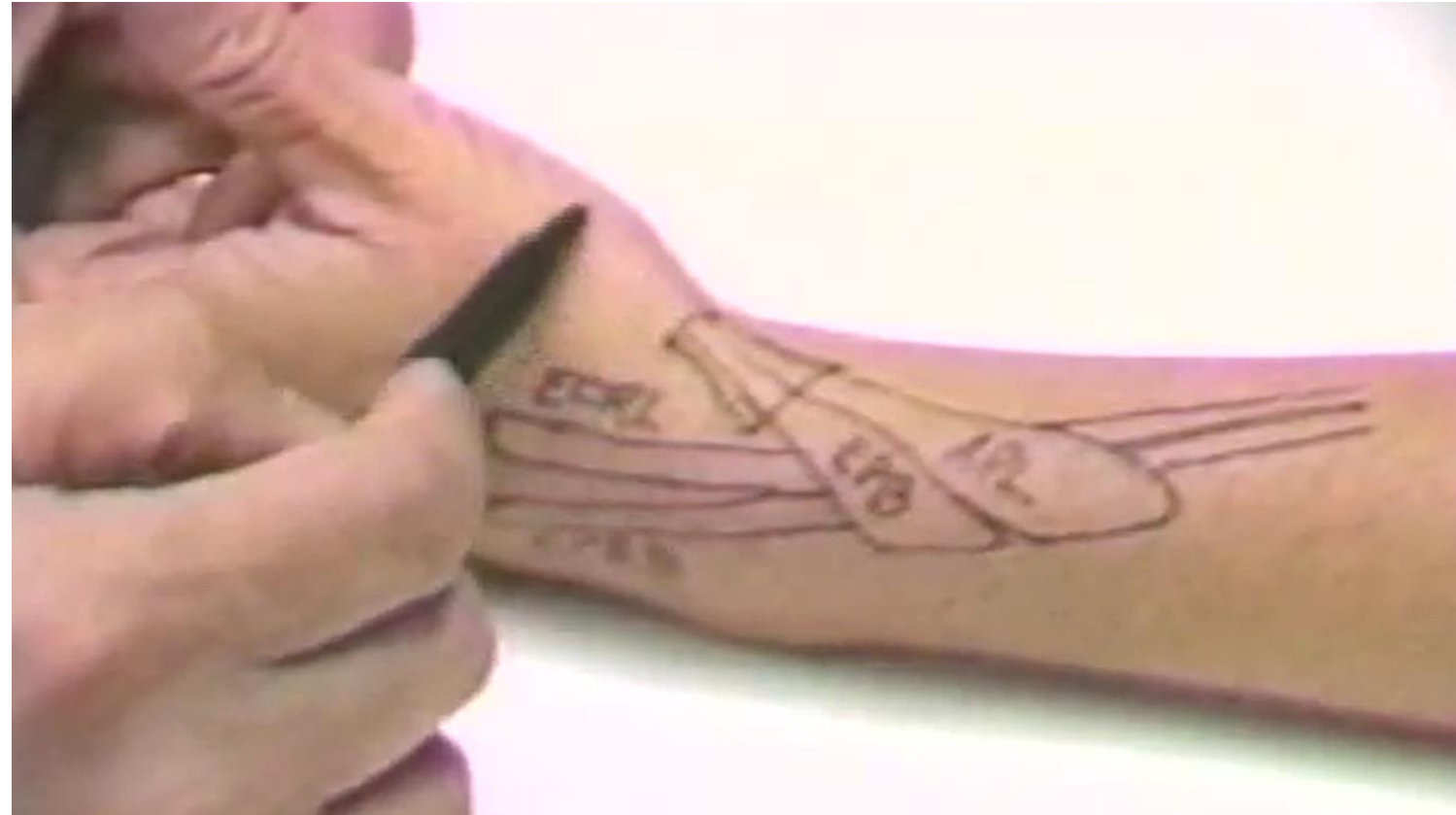Palpation

- Logical sequence
- Start at asymptomatic area
- Palpate all key structures
- Radial / Central / Ulnar



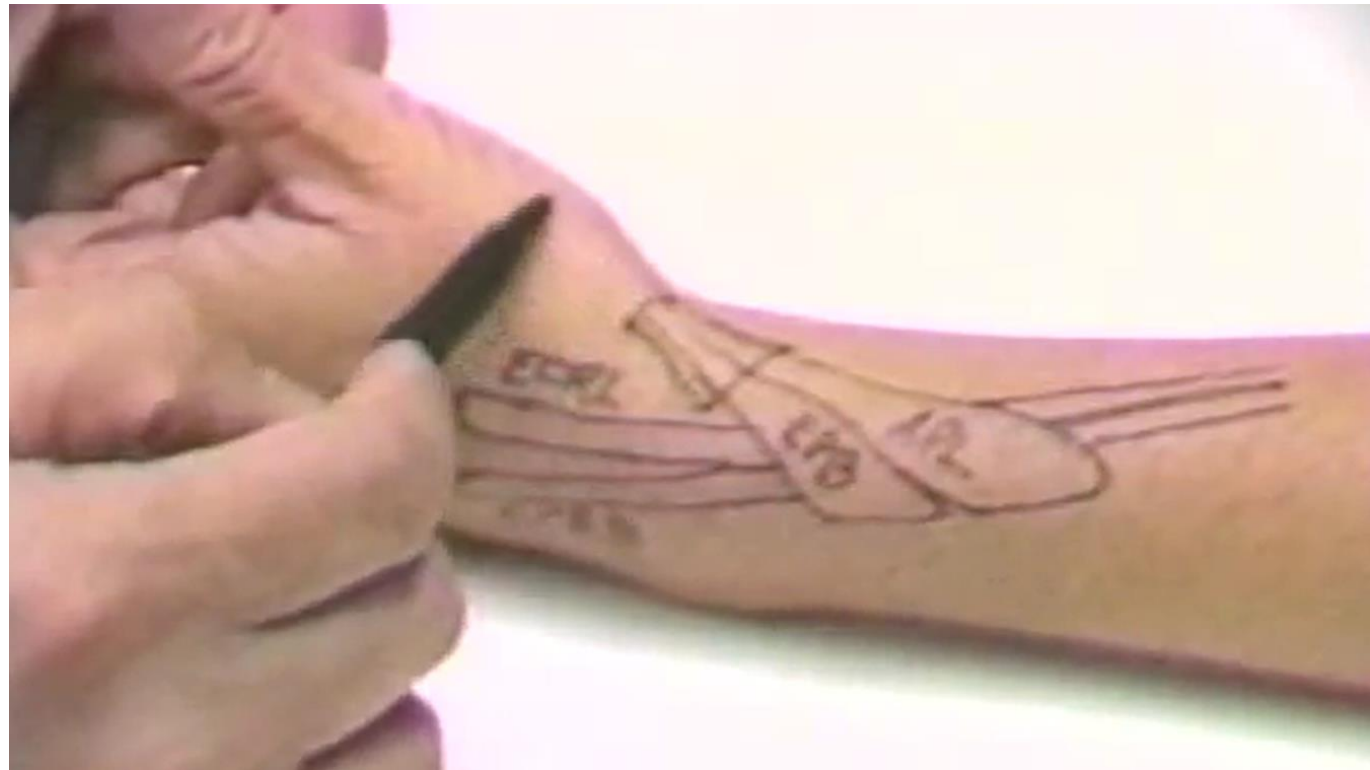Radial Tenderness

- **Proximal to radial styloid**
 - Intersection Syndrome



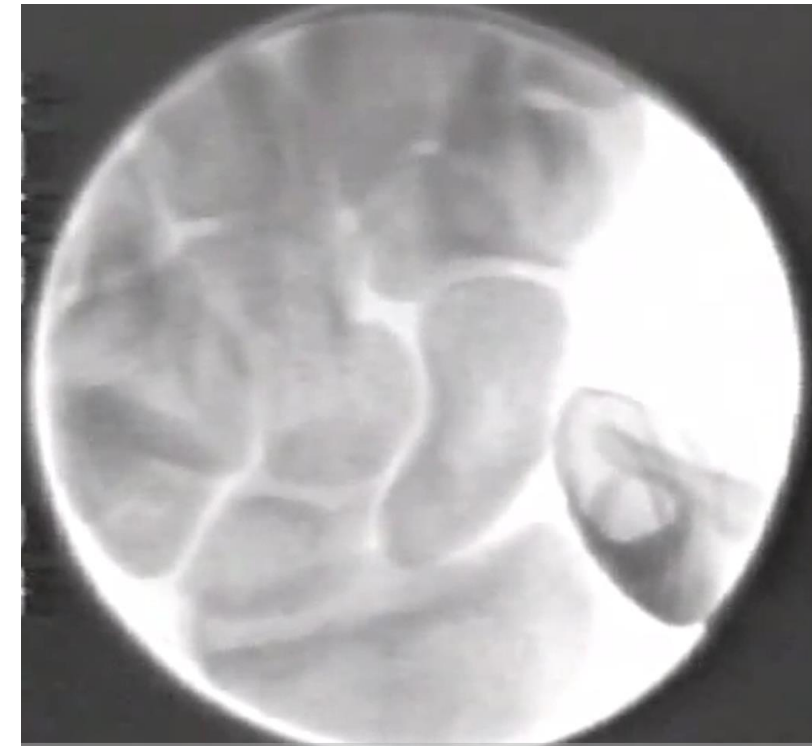
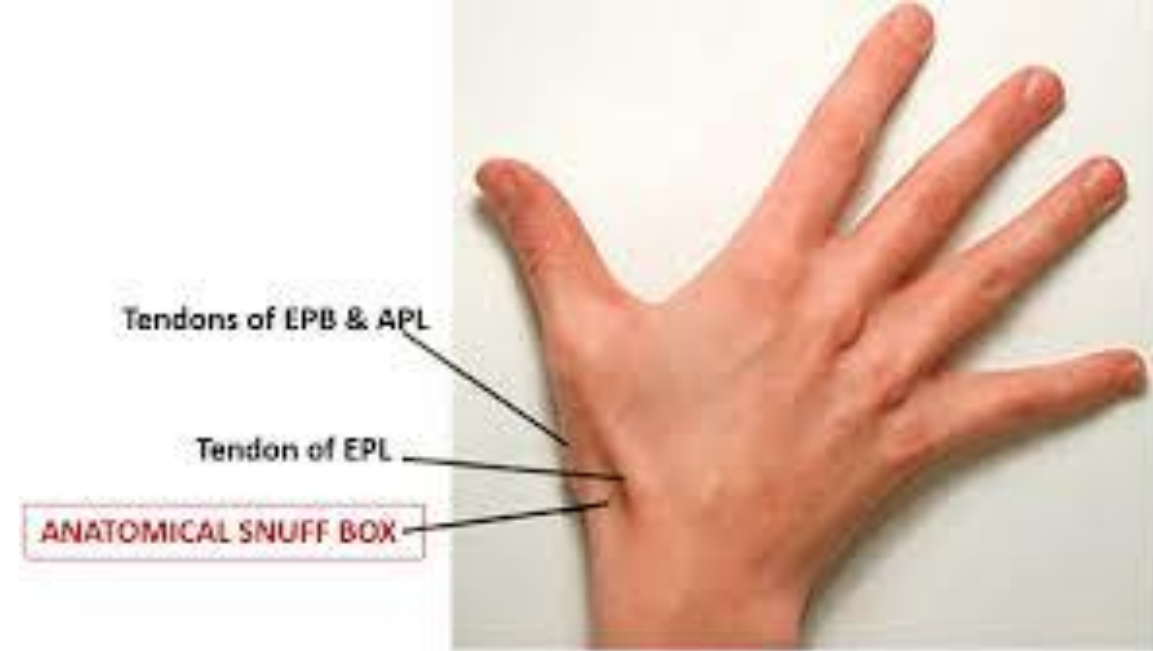
Radial Tenderness

- Proximal to radial styloid (IS)
- **Radial styloid**
 - De Quervains Tenosynovitis



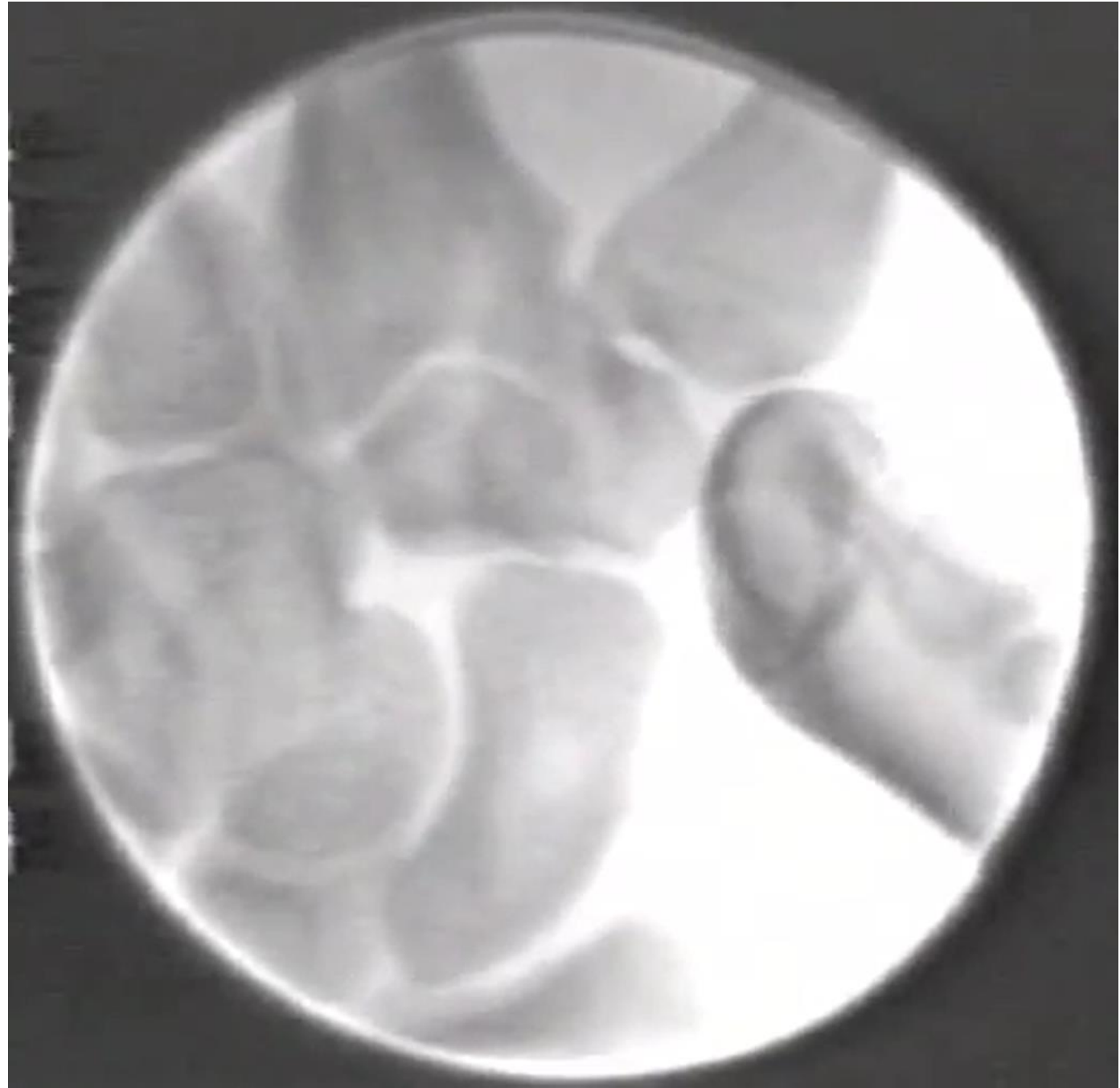
Radial Tenderness

- Proximal to radial styloid (IS)
- Radial styloid (DQ)
- **Anatomical snuff box**
 - Scaphoid waist



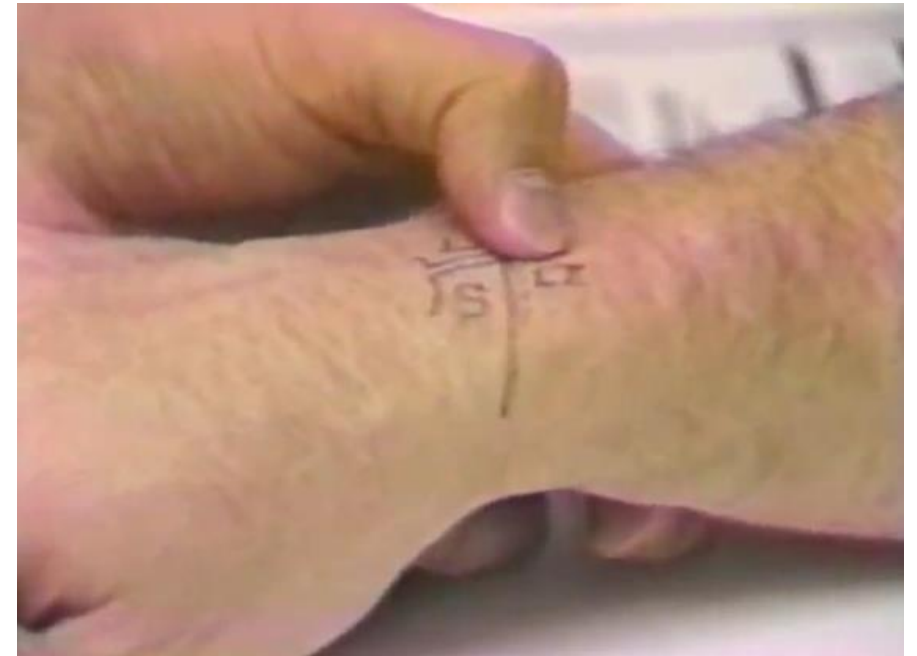Radial Tenderness

- Proximal to radial styloid (IS)
- Radial styloid (DQ)
- **Anatomical snuff box**
 - Scaphoid waist
 - **Base of thumb**
 - CMC1 OA
 - CMC1 instability
 - STT OA



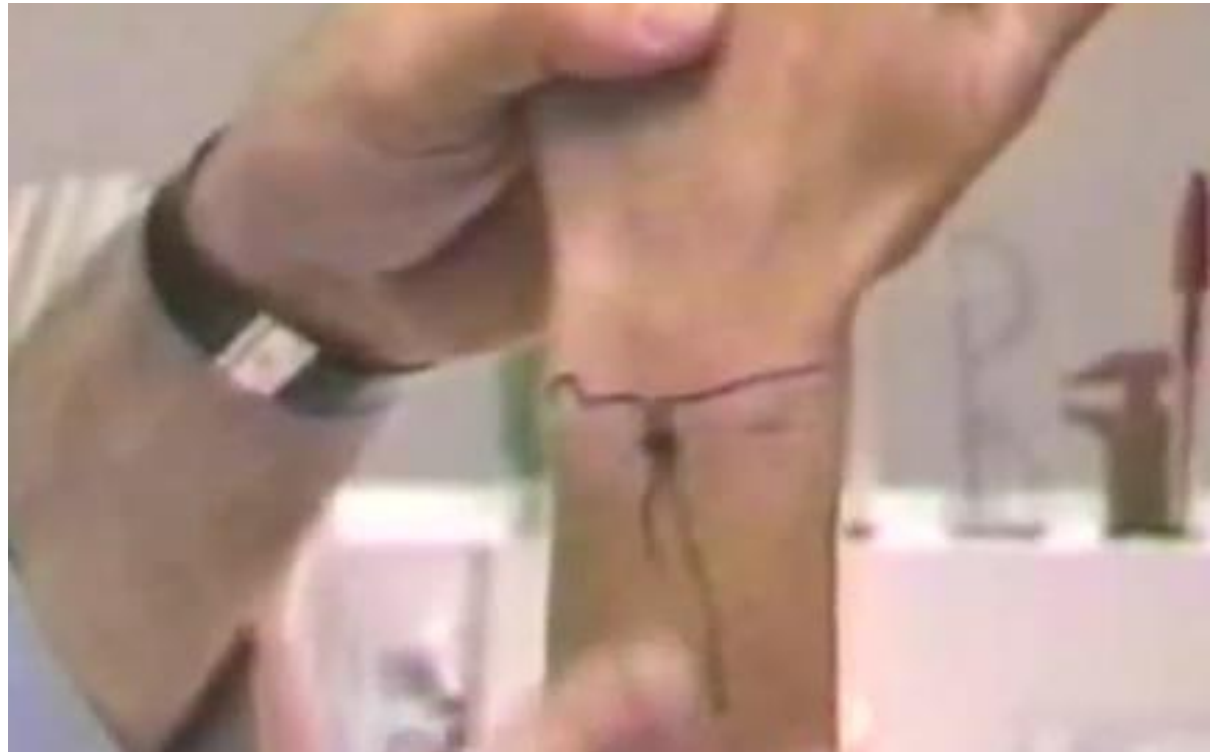Radial Tenderness

- Proximal to radial styloid (IS)
- Radial styloid (DQ)
- Anatomical snuff box (Scaph)
- Base of thumb (OA, instability)
- **Scapholunate Interosseous ligament (SLIL)**
 - SLIL injury
 - Occult ganglion
 - Scaphoid proximal pole #



Central Tenderness

- **Lunate**
 - Kienbochs

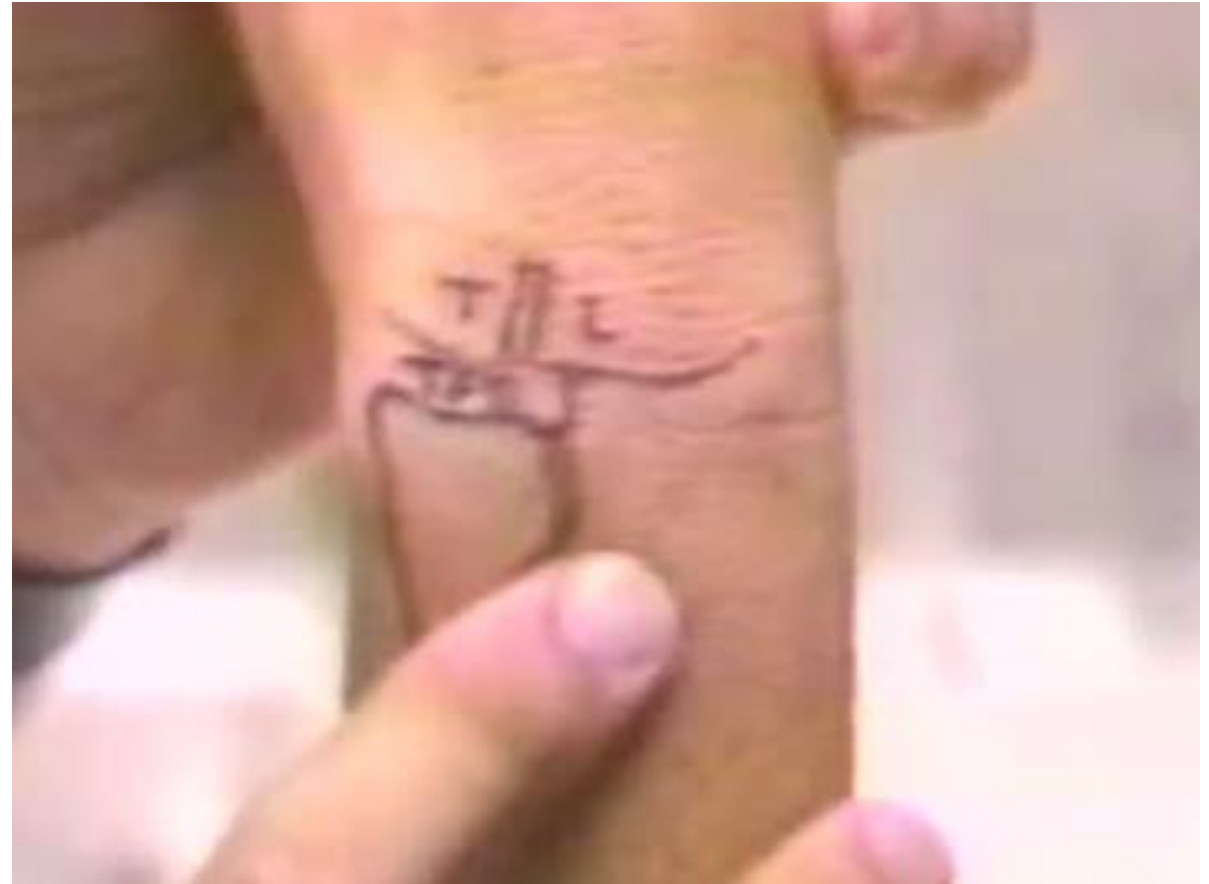

Central Tenderness

- Lunate
- **2nd & 3rd CMCJ**
 - Synovitis

Ulnar Tenderness

- **Lunotriquetral interosseous ligament**
 - Injury / instability



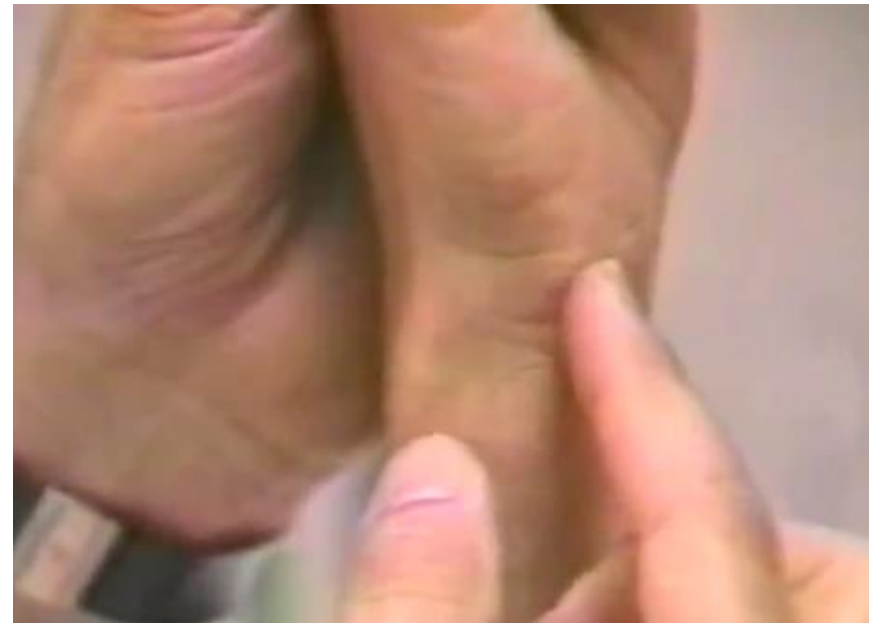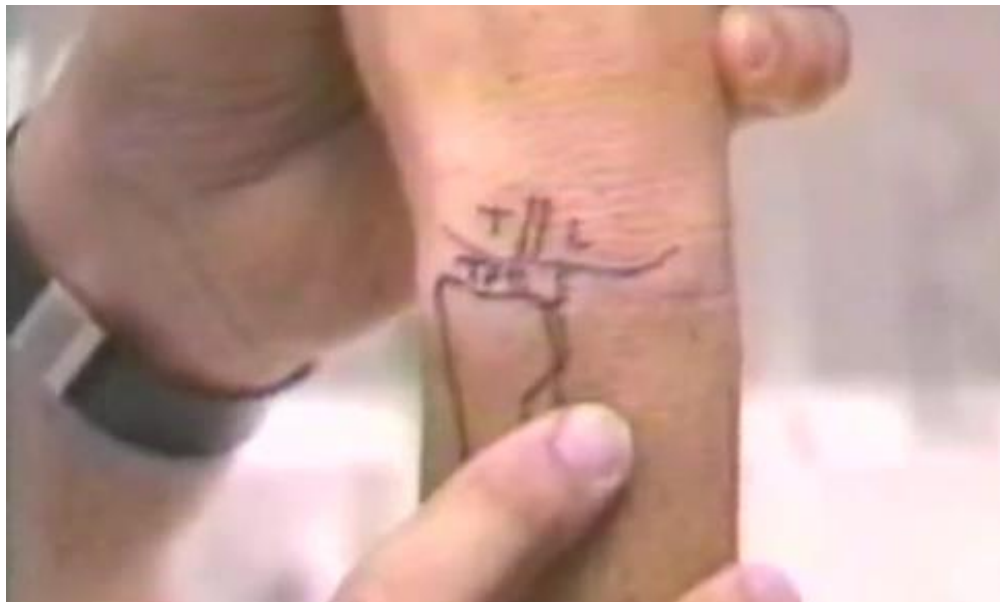Ulnar Tenderness

- Lunotriquetral interosseous ligament
- **Distal Radioulnar joint**
 - Arthritis
 - Instability
 - Injury



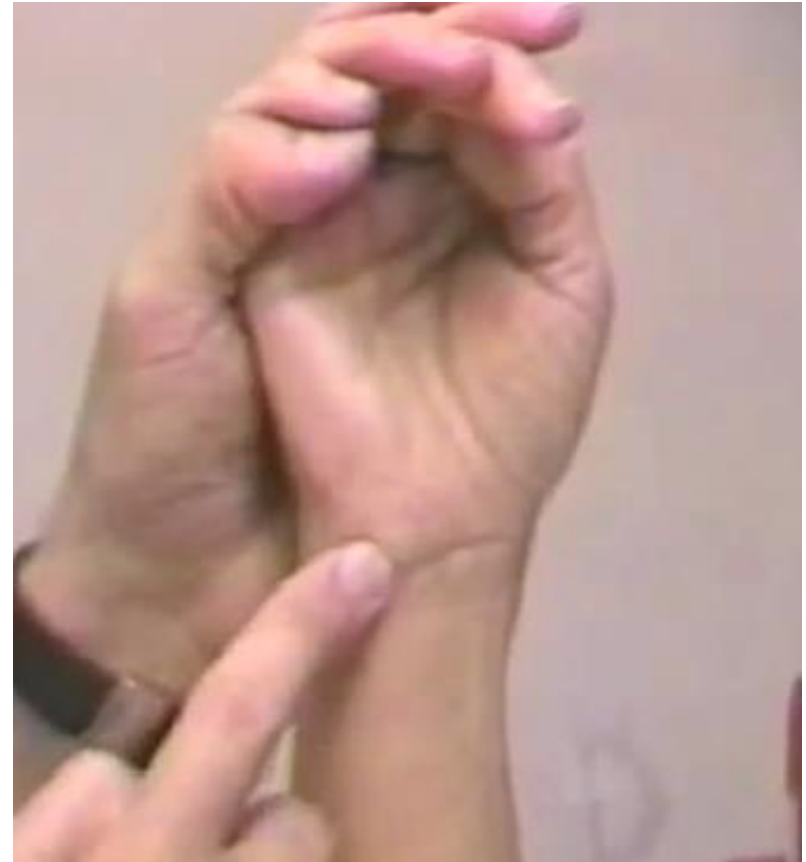Ulnar Tenderness

- Lunotriquetral interosseous ligament
- Distal Radioulnar joint
- **TFCC**
 - Injury / synovitis



Ulnar Tenderness

- Lunotriquetral interosseous ligament
- Distal Radioulnar joint
- TFCC
- **Pisiform**
 - OA



Ulnar Tenderness

- Lunotriquetral interosseous ligament
- Distal Radioulnar joint
- TFCC
- Pisiform
- **ECU**
 - Instability
 - Tenosynovitis

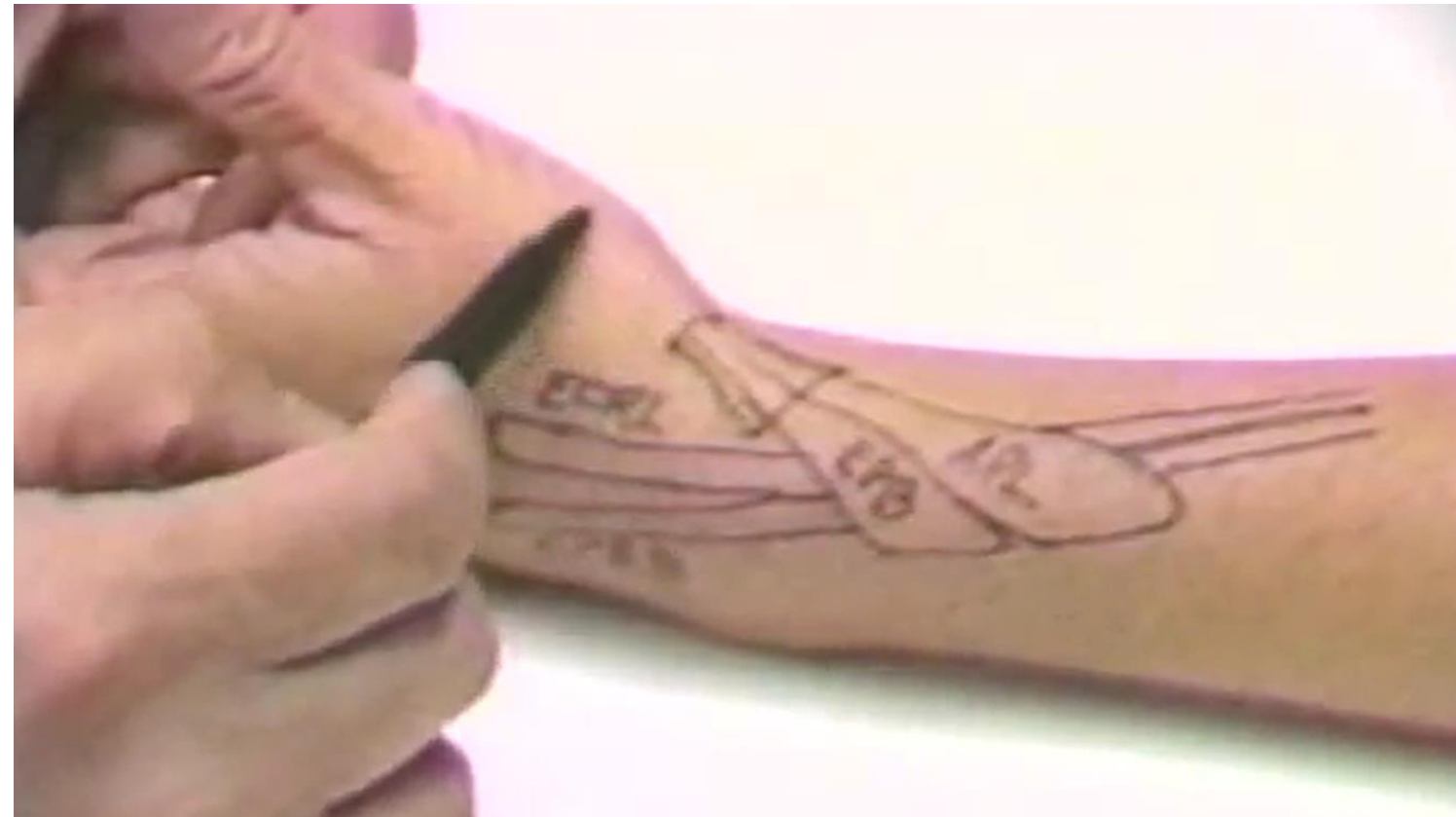

Provocative Manoeuvres

- Designed to elicit physical findings, aid the diagnosis of specific pathology

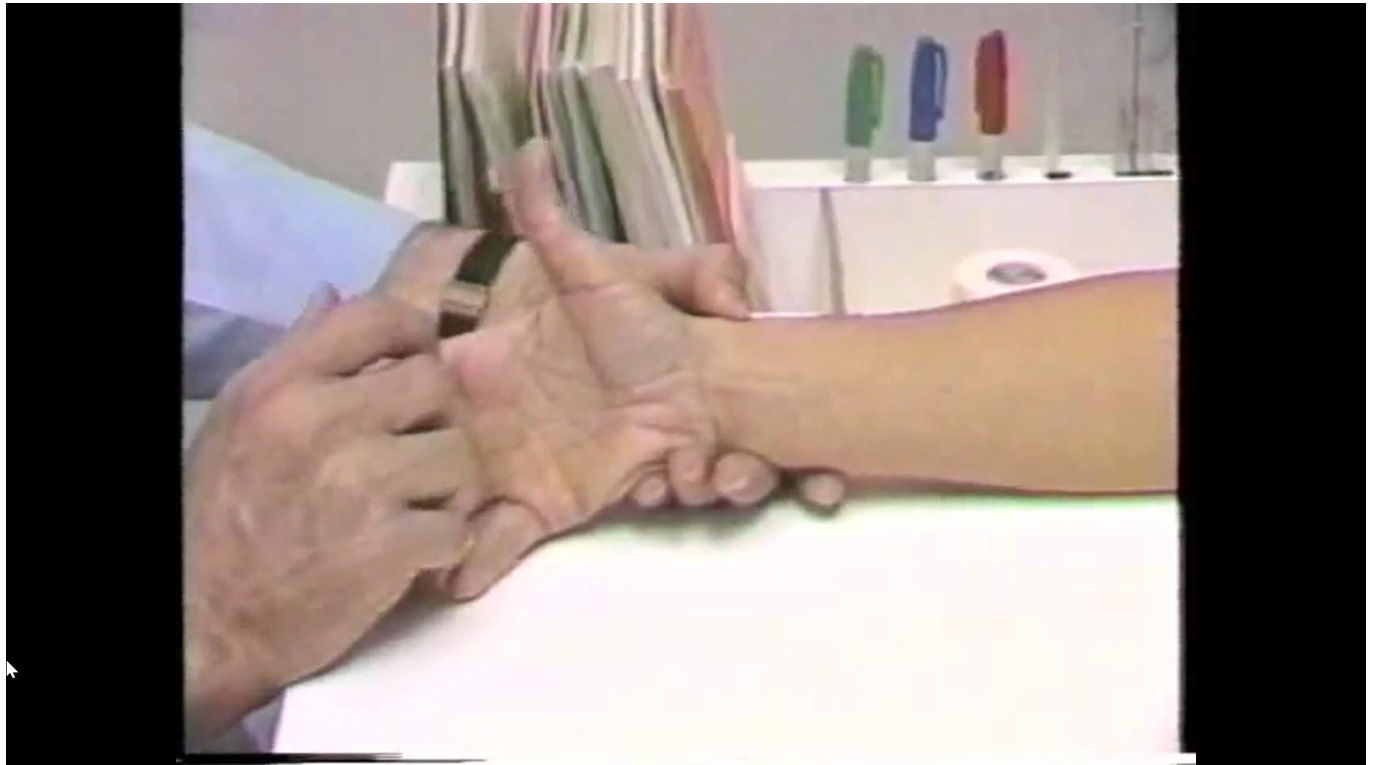Provocative Manoeuvres – Intersection Syndrome

- Wrist Ext / Thumb Ext



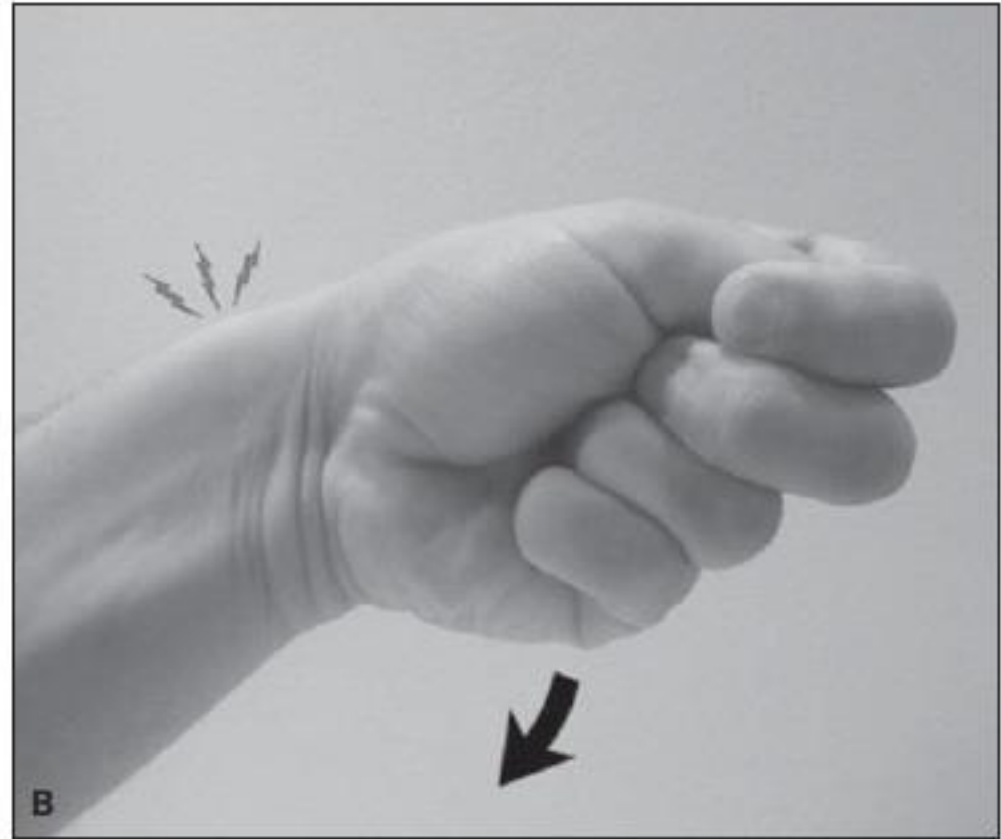
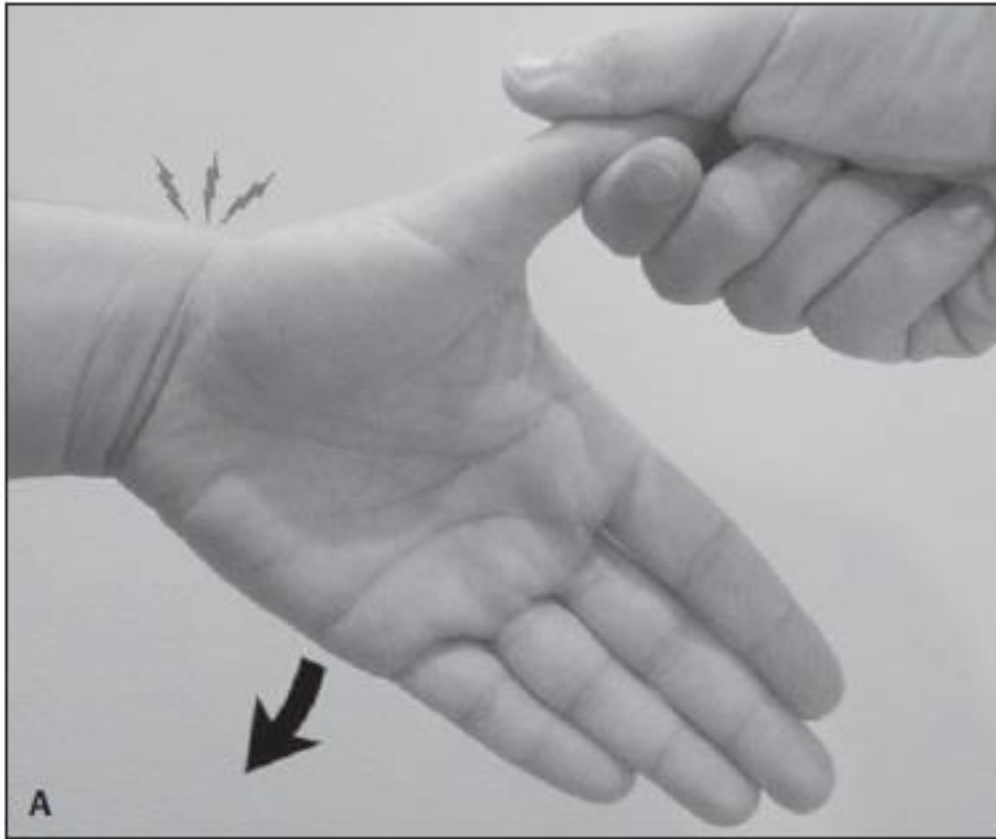
Provocative Manoeuvres – De Quervains

- **Modified Eichhoff / Finklesteins**

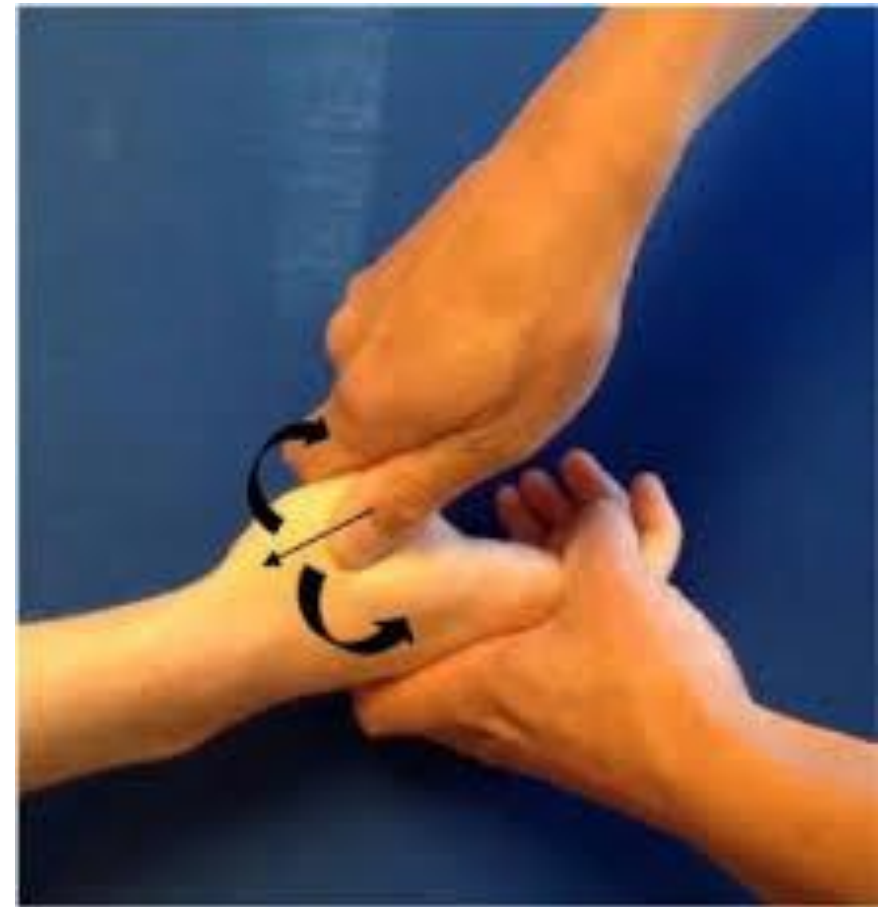
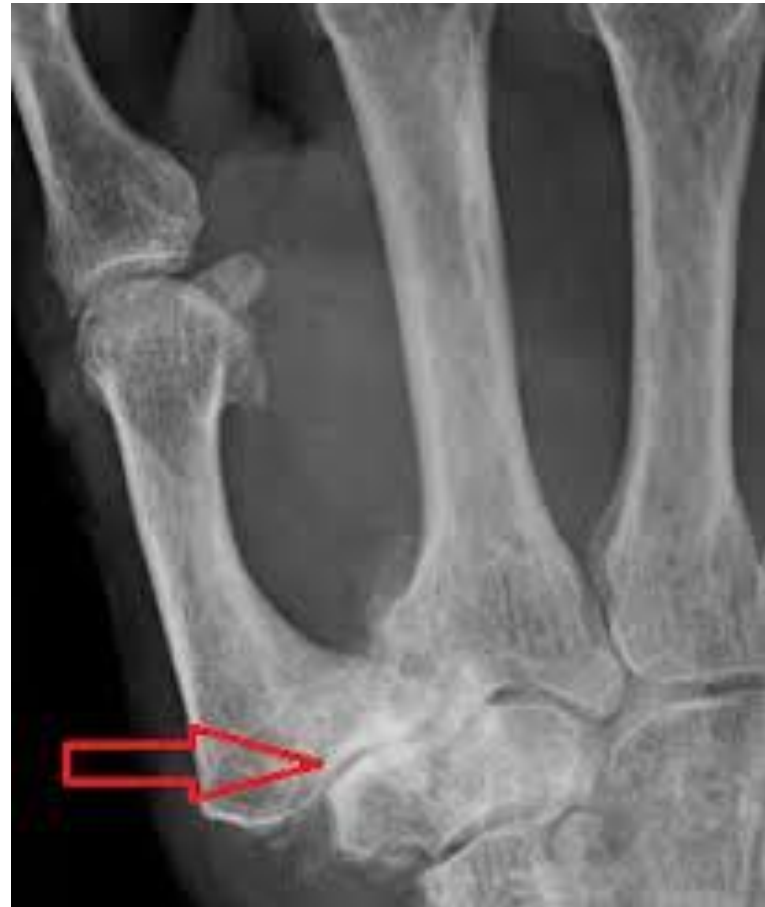
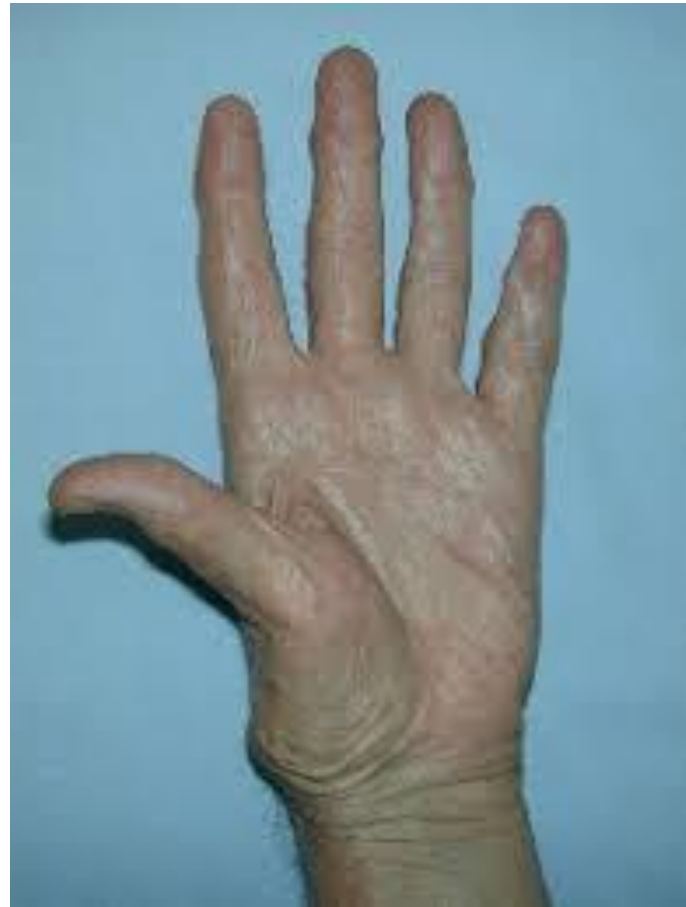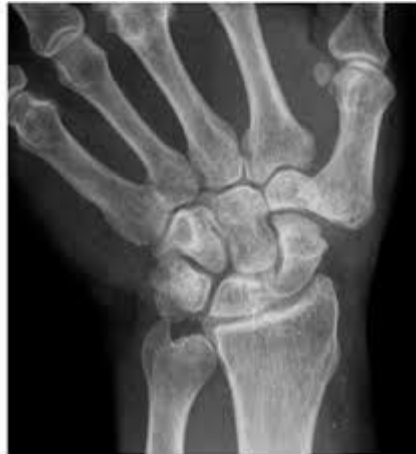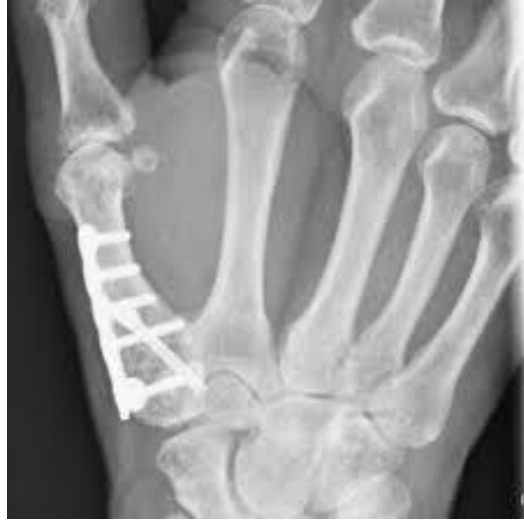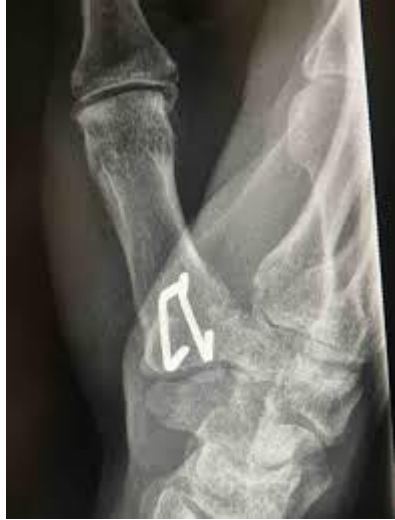Provocative Manoeuvres – De Quervains

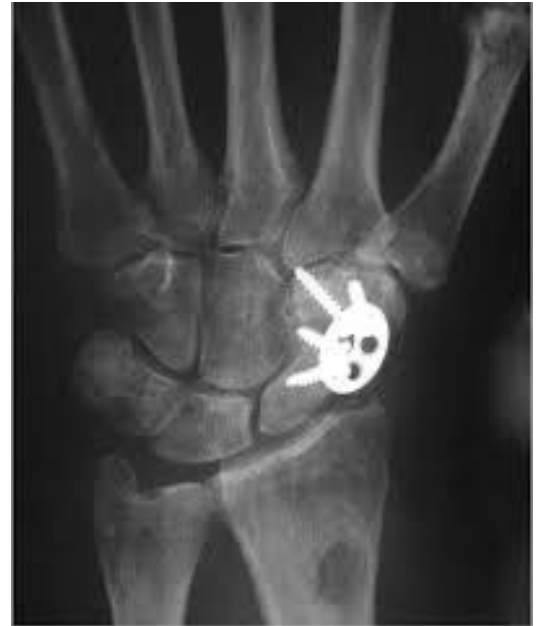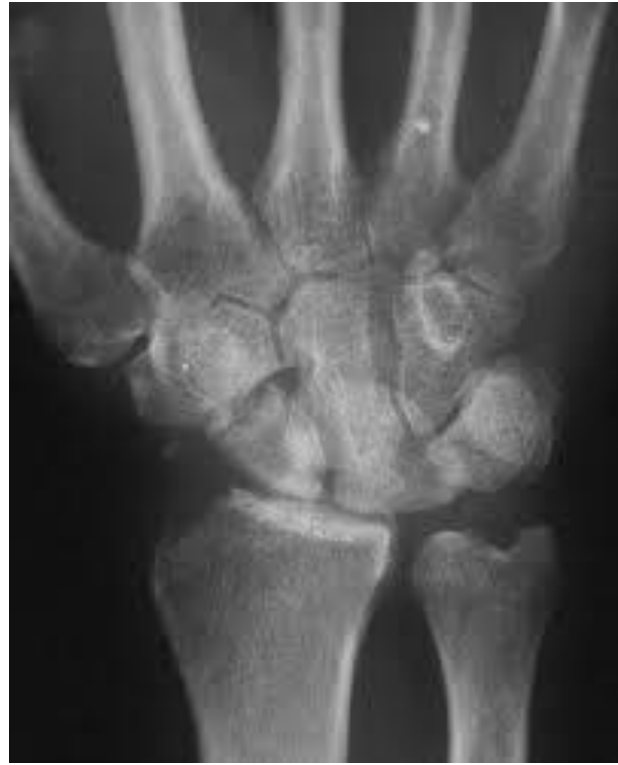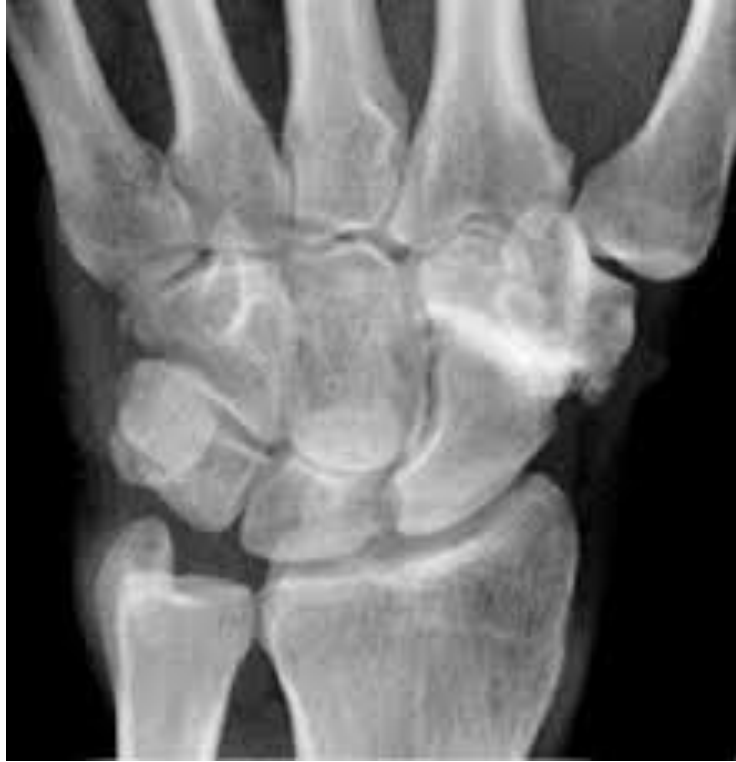-



Provocative Manoeuvres – CMC 1

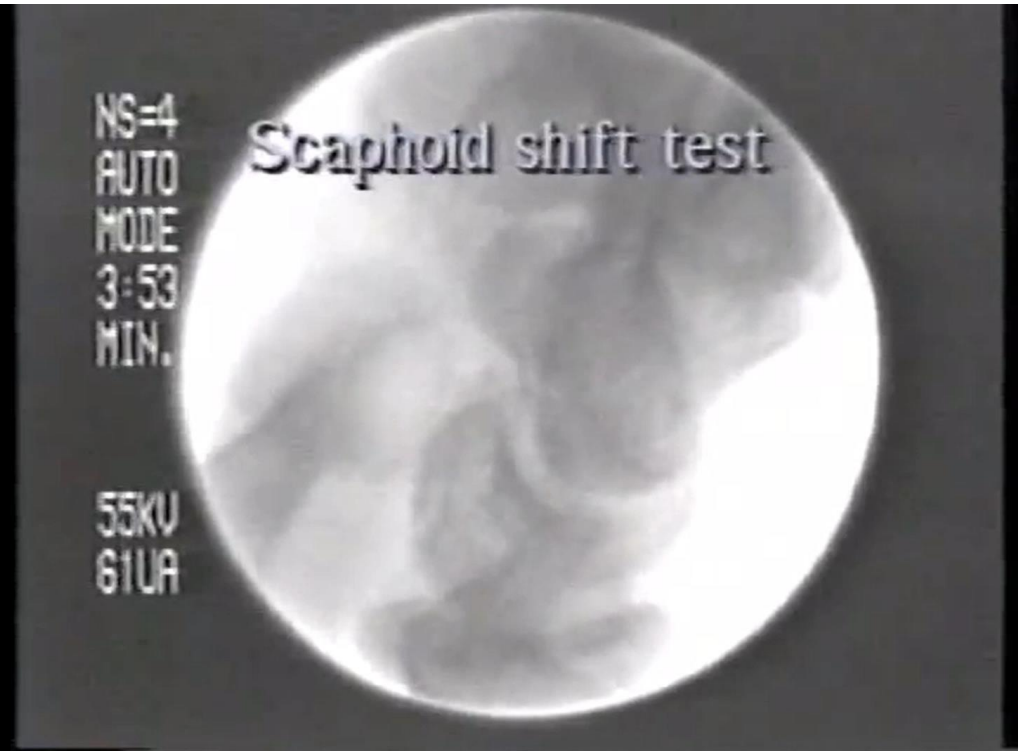
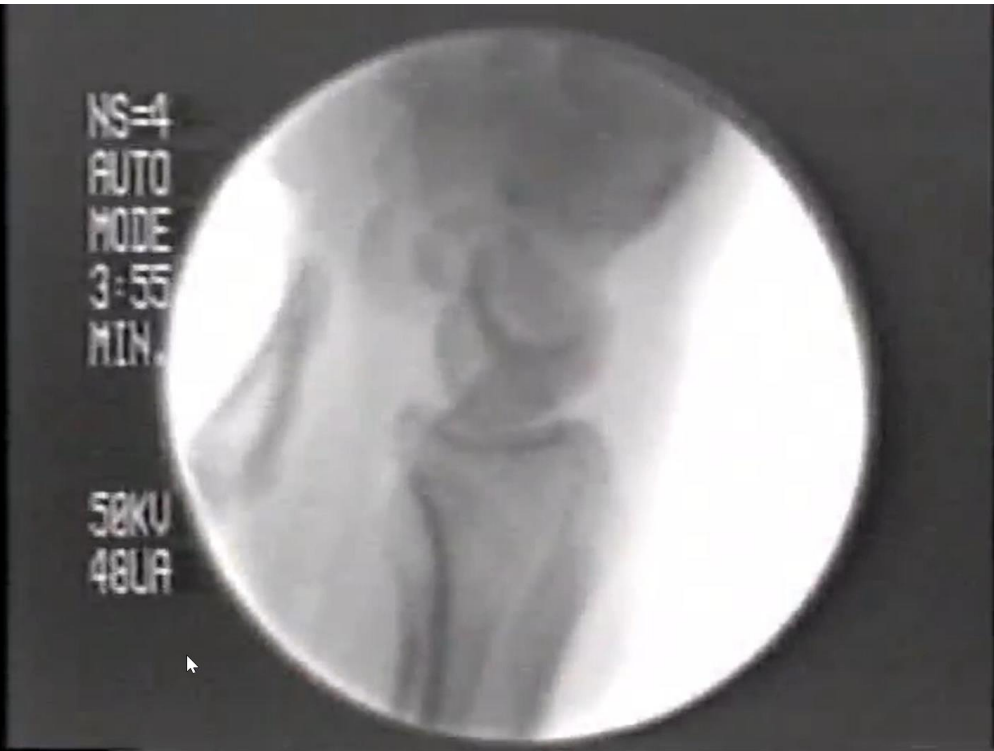




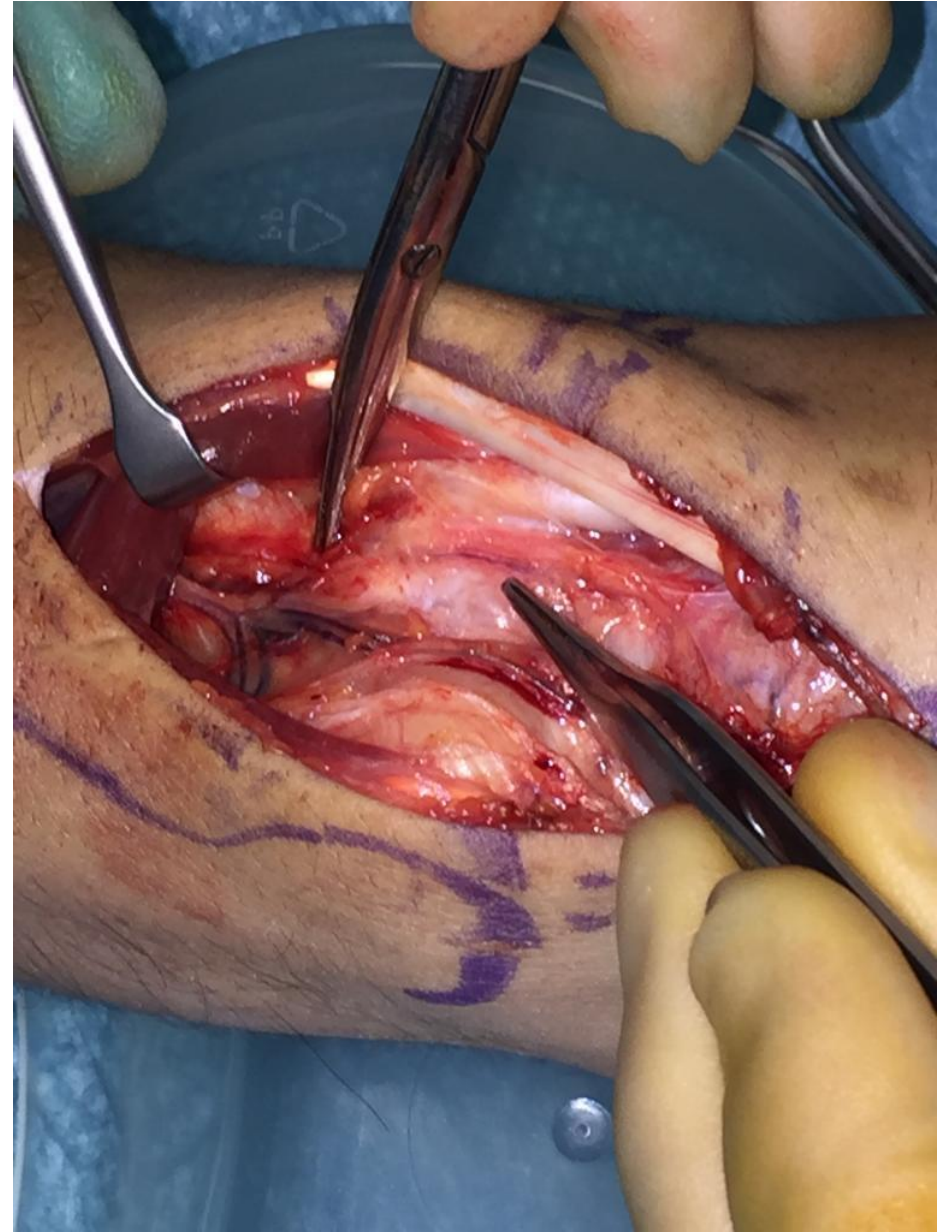
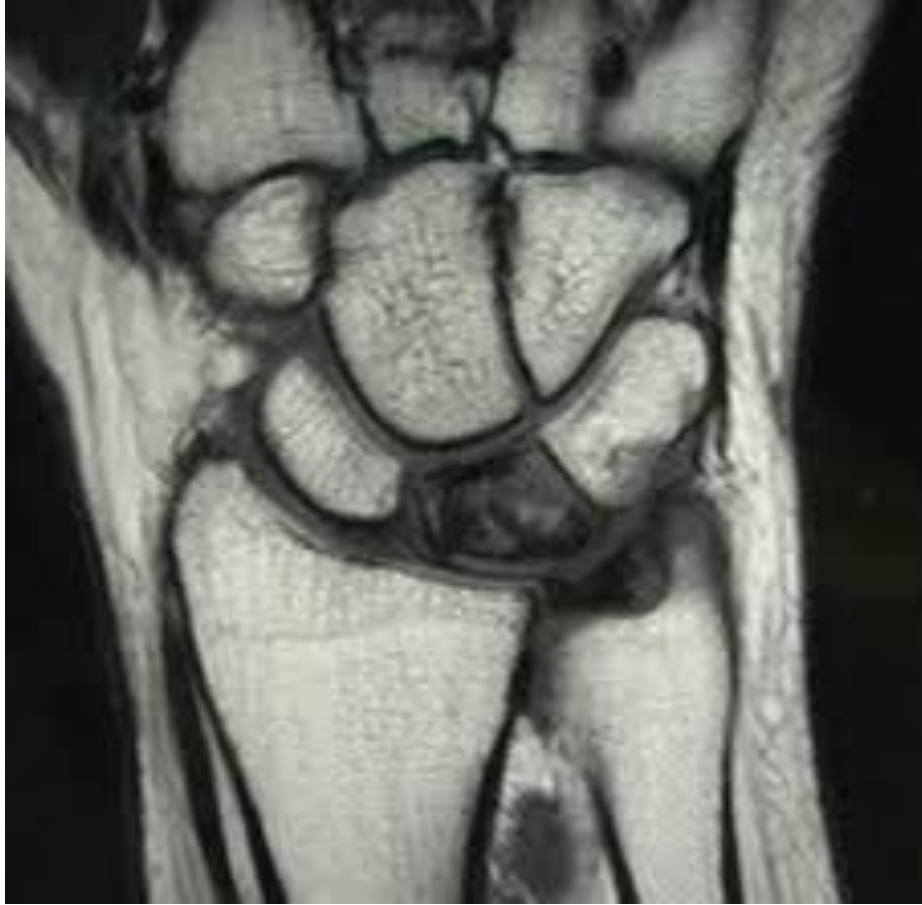Provocative Manoeuvres – Carpal Instability

- **Scaphoid Shift**
 - SLIL instability

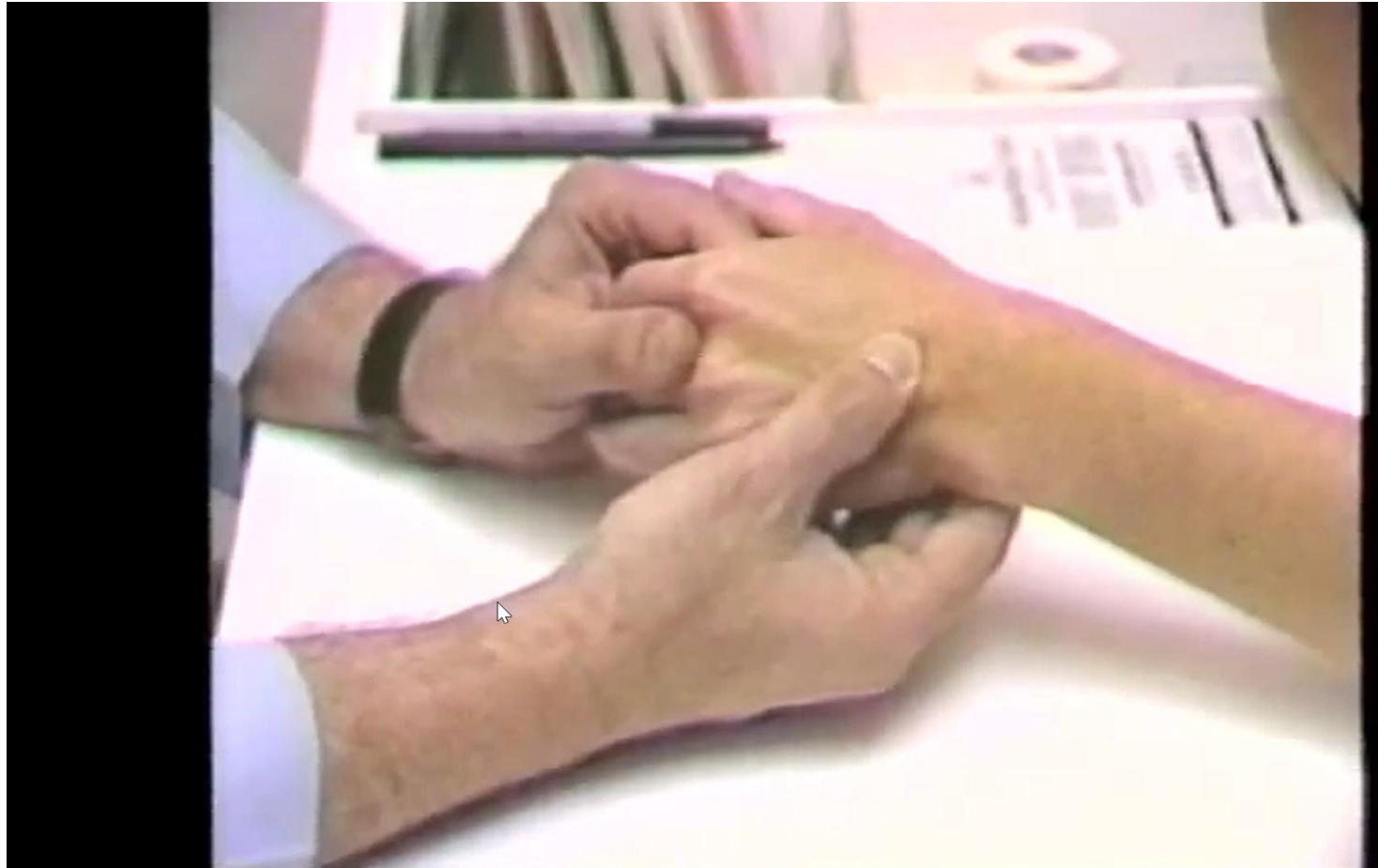

Kienbochs



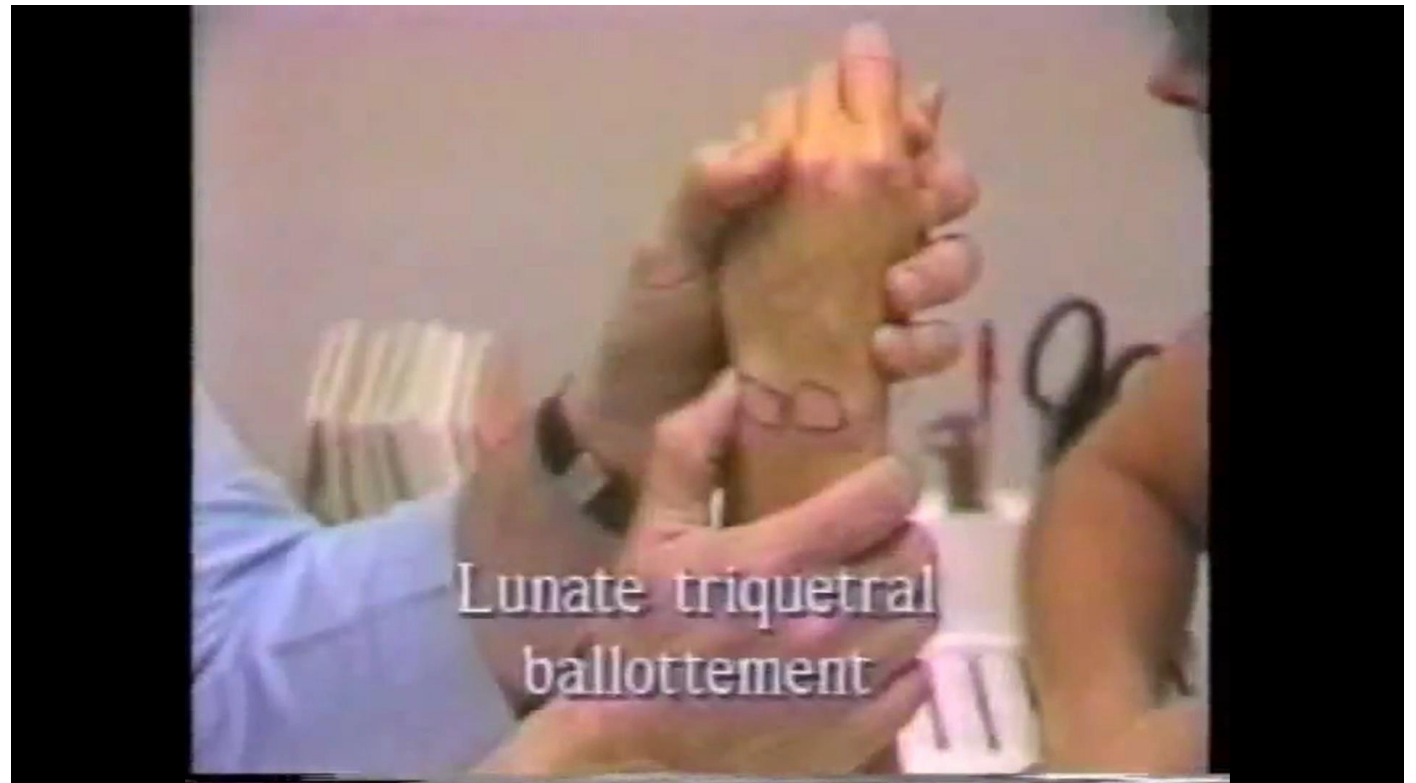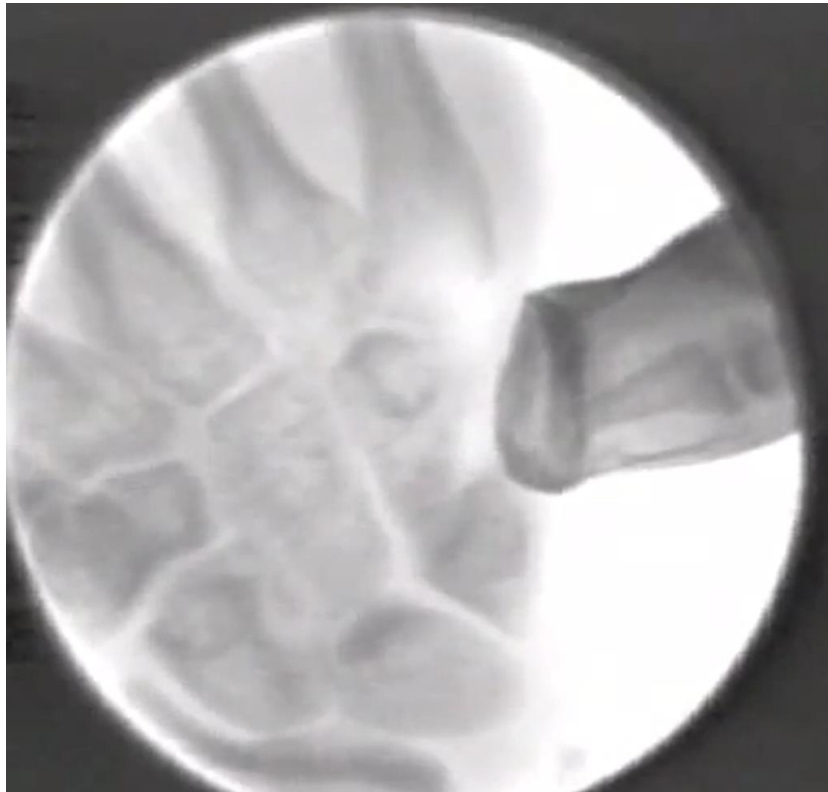Provocative Manoeuvres – CMCJ synovitis

- Handshake test



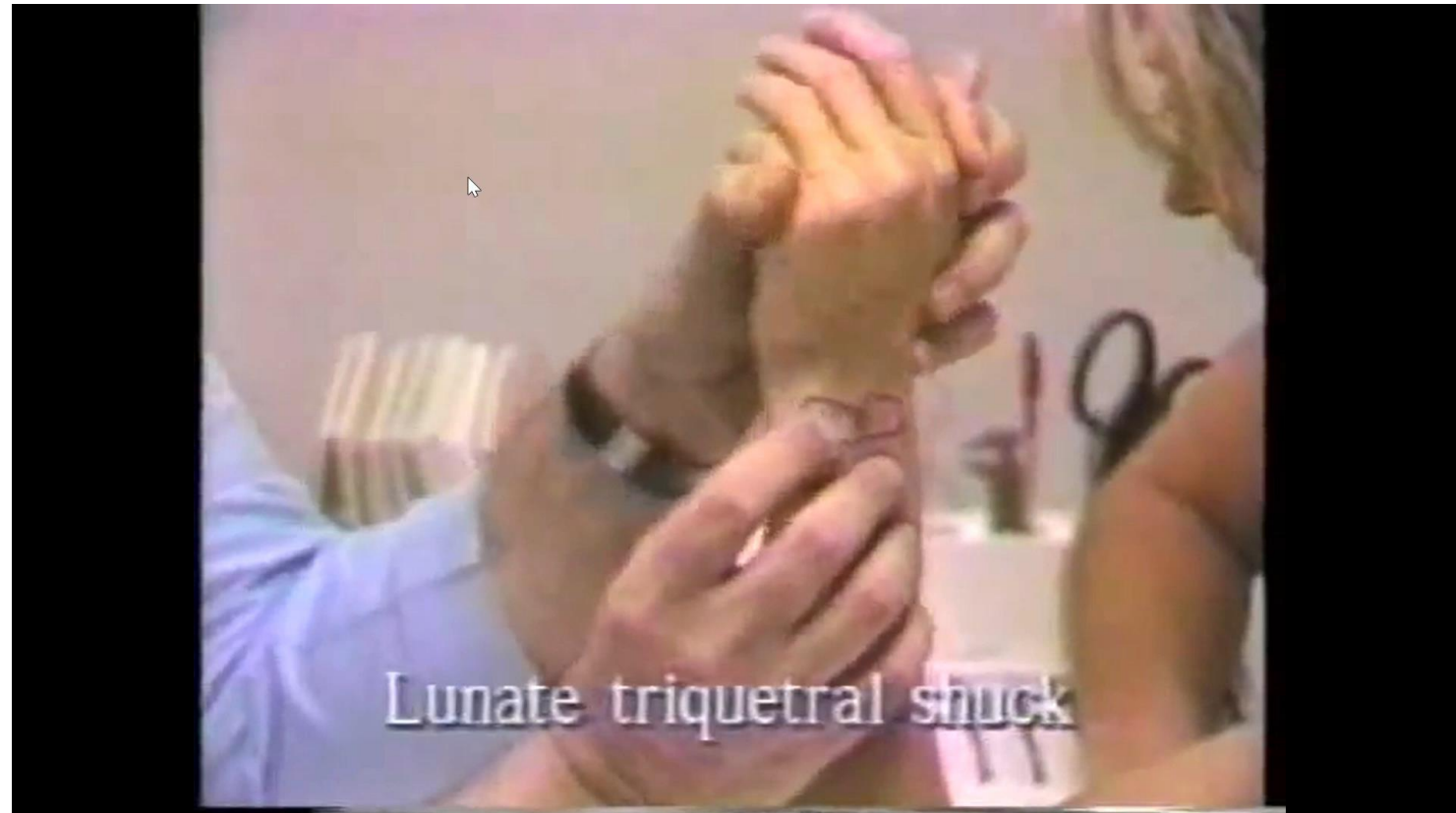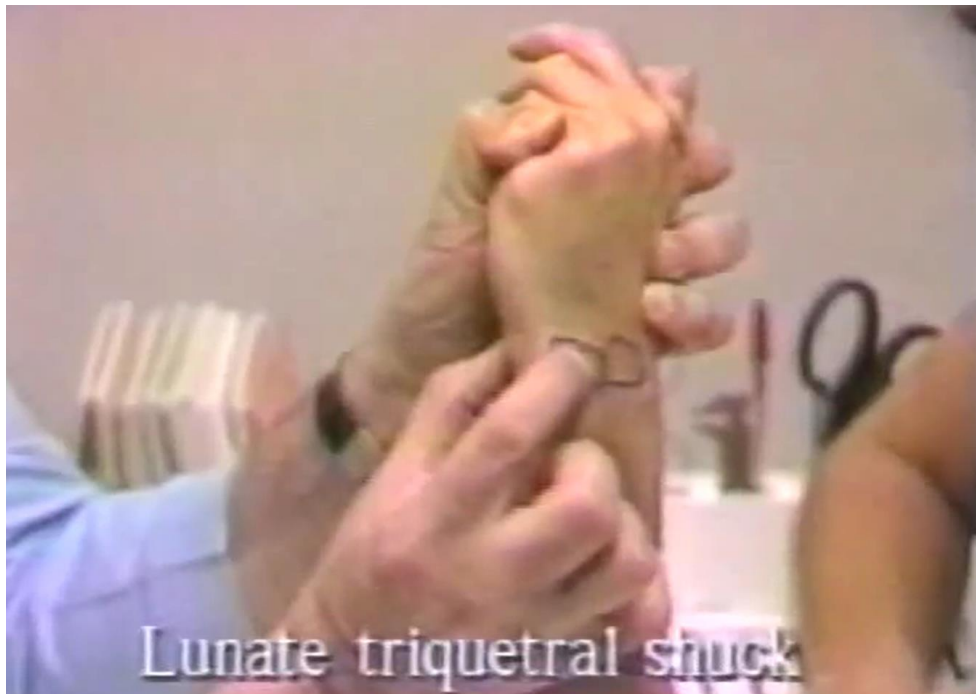Provocative Manoeuvres – Carpal Instability

- LTIL
 - **Ballottement**



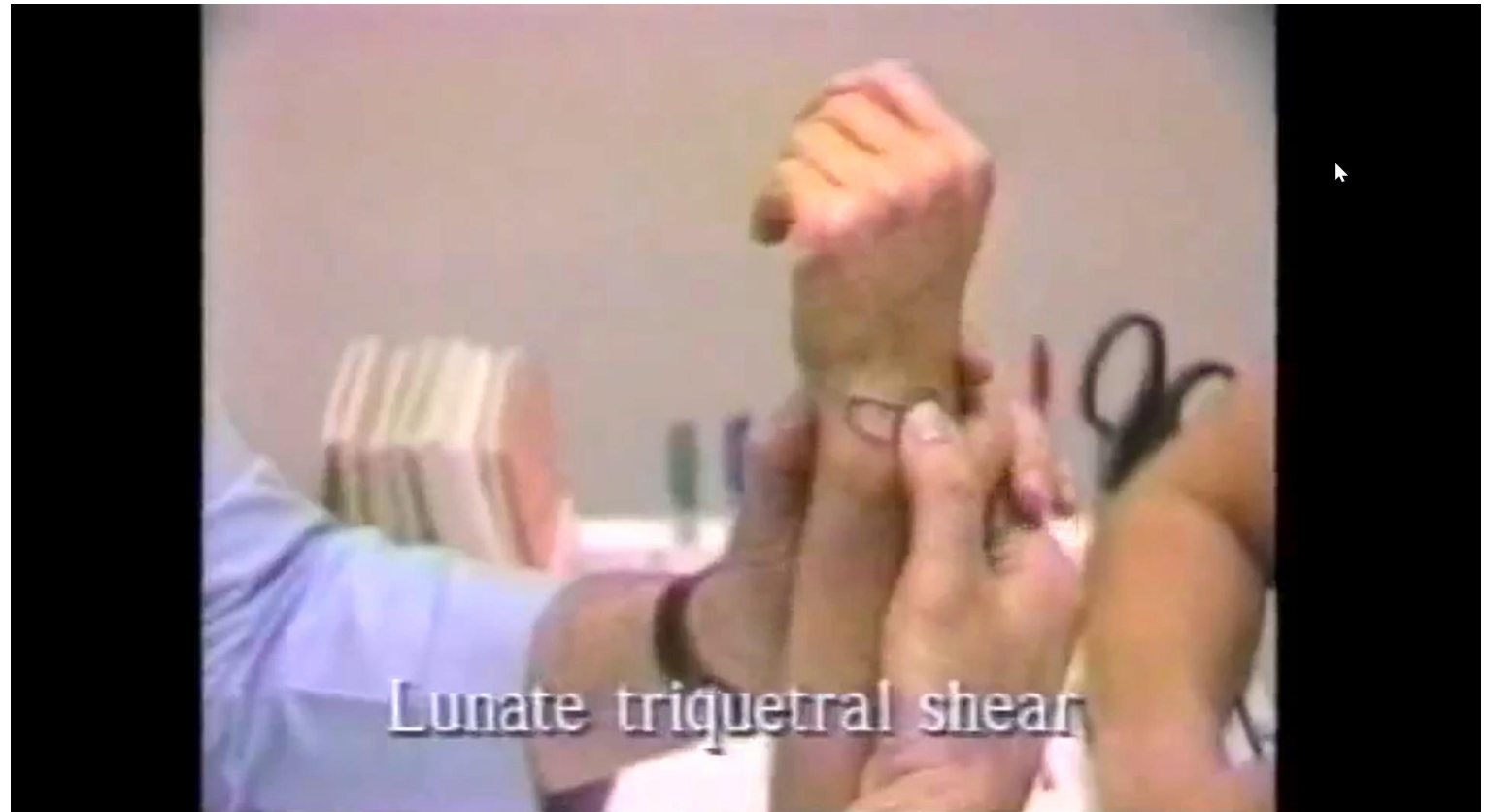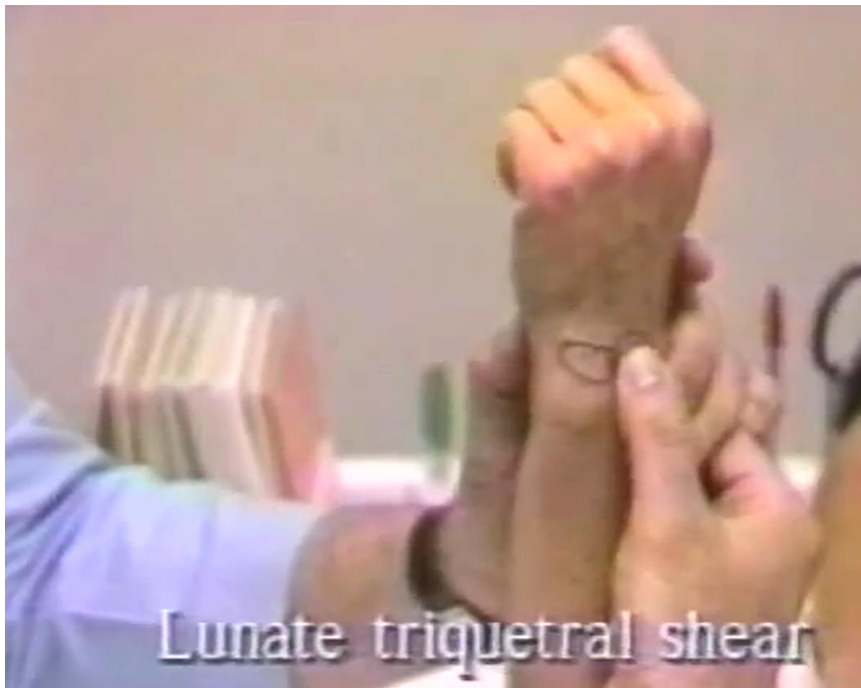Provocative Manoeuvres – Carpal Instability

- LTIL
 - Ballottement
 - **Shuck**



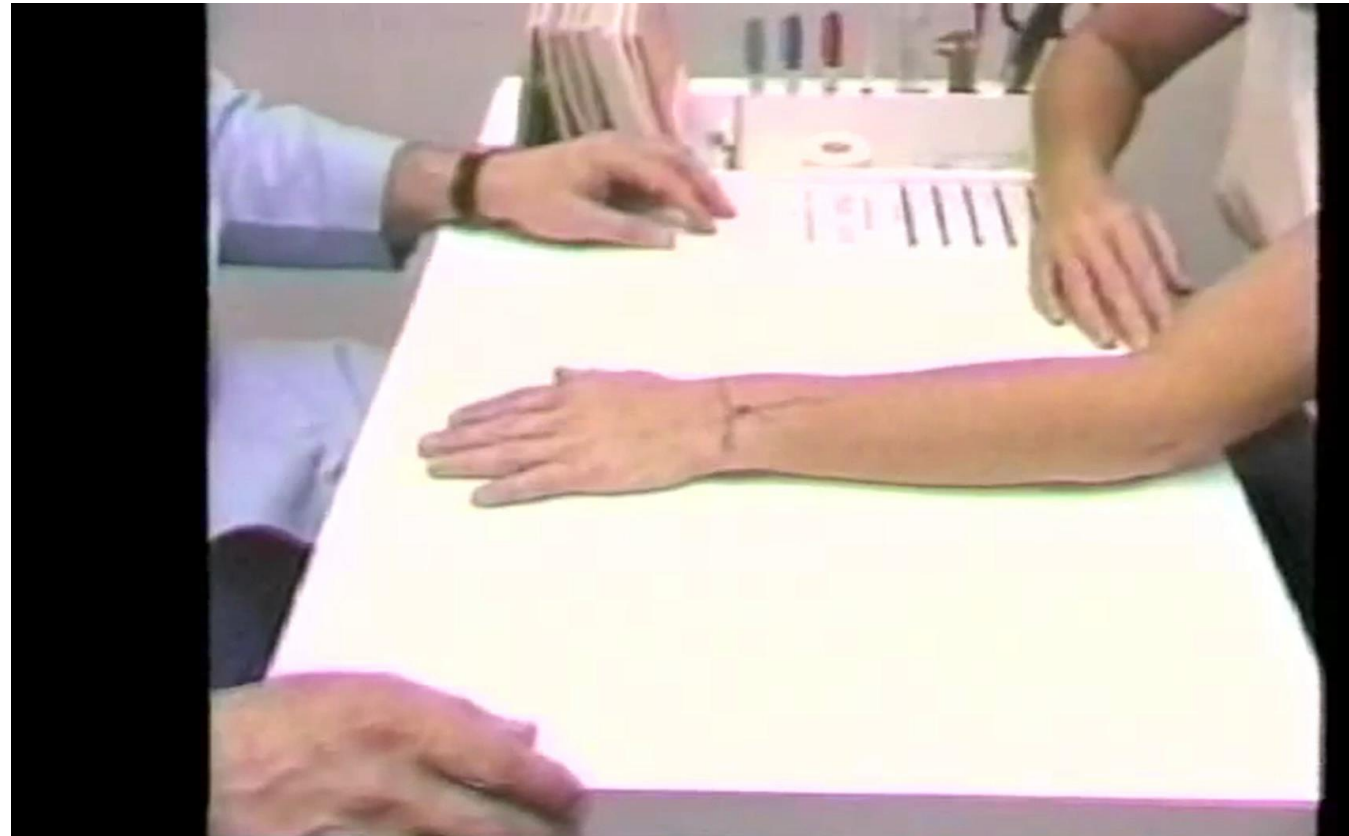
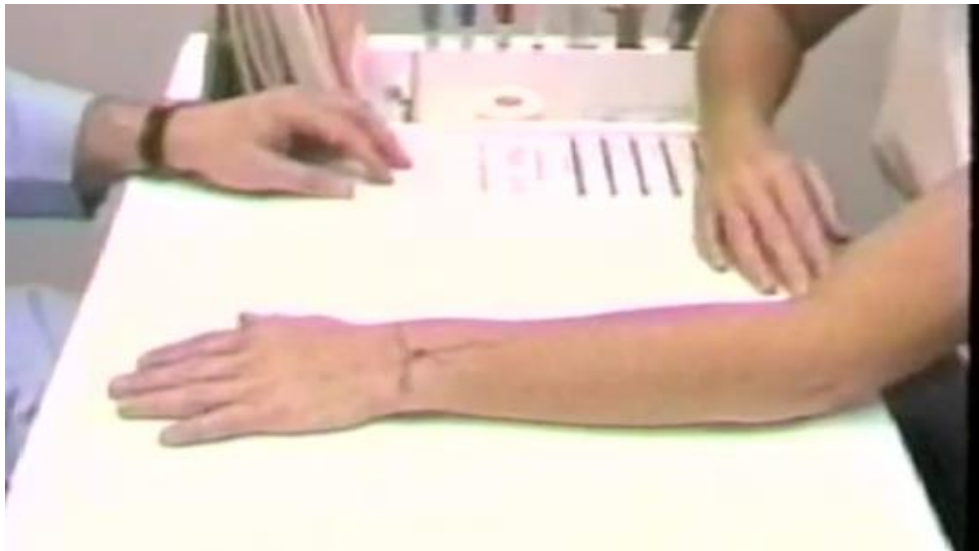Provocative Manoeuvres – Carpal Instability

- LTIL
 - Ballottement
 - Shuck
 - **Shear**



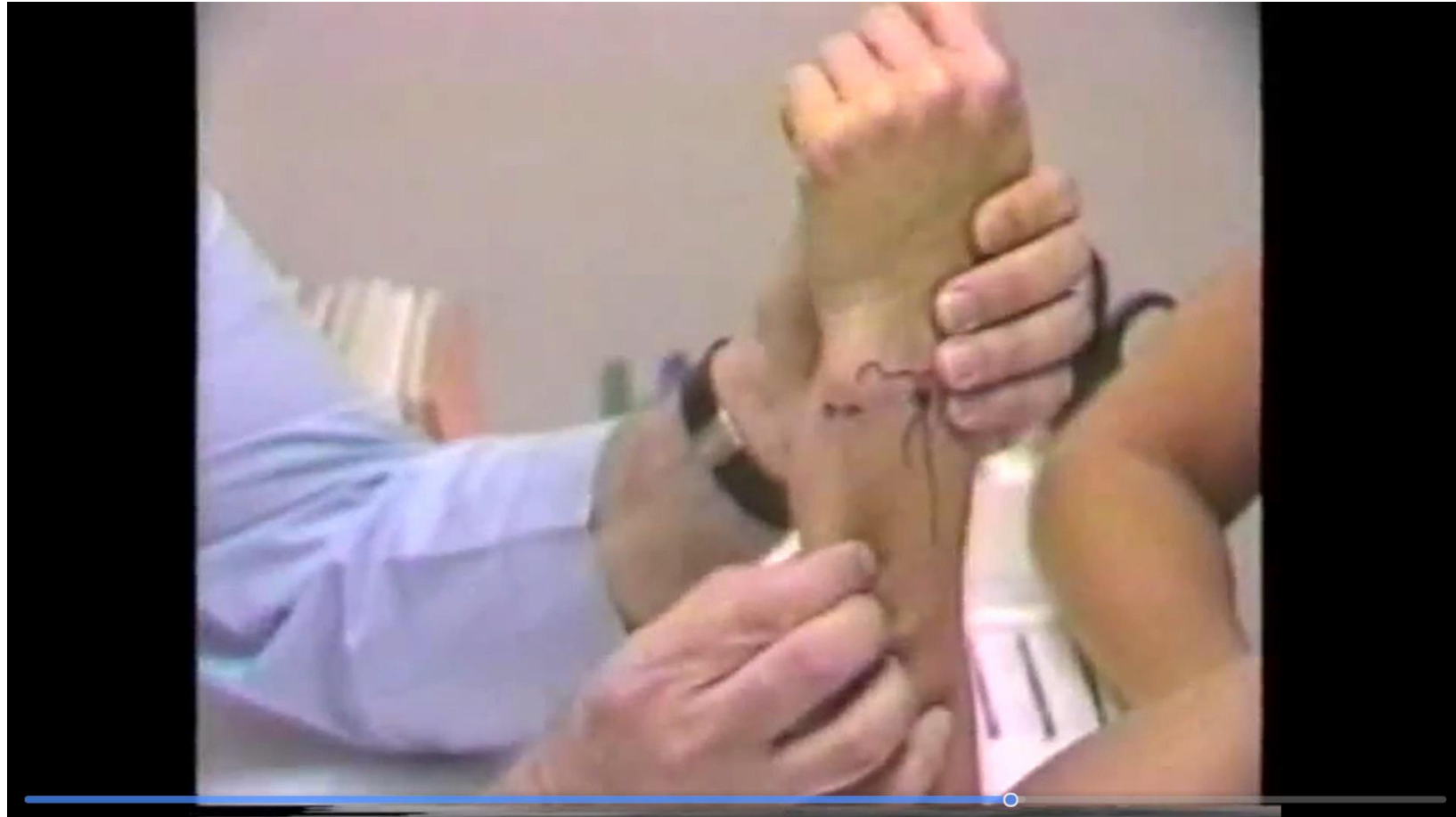Provocative Manoeuvres - DRUJ

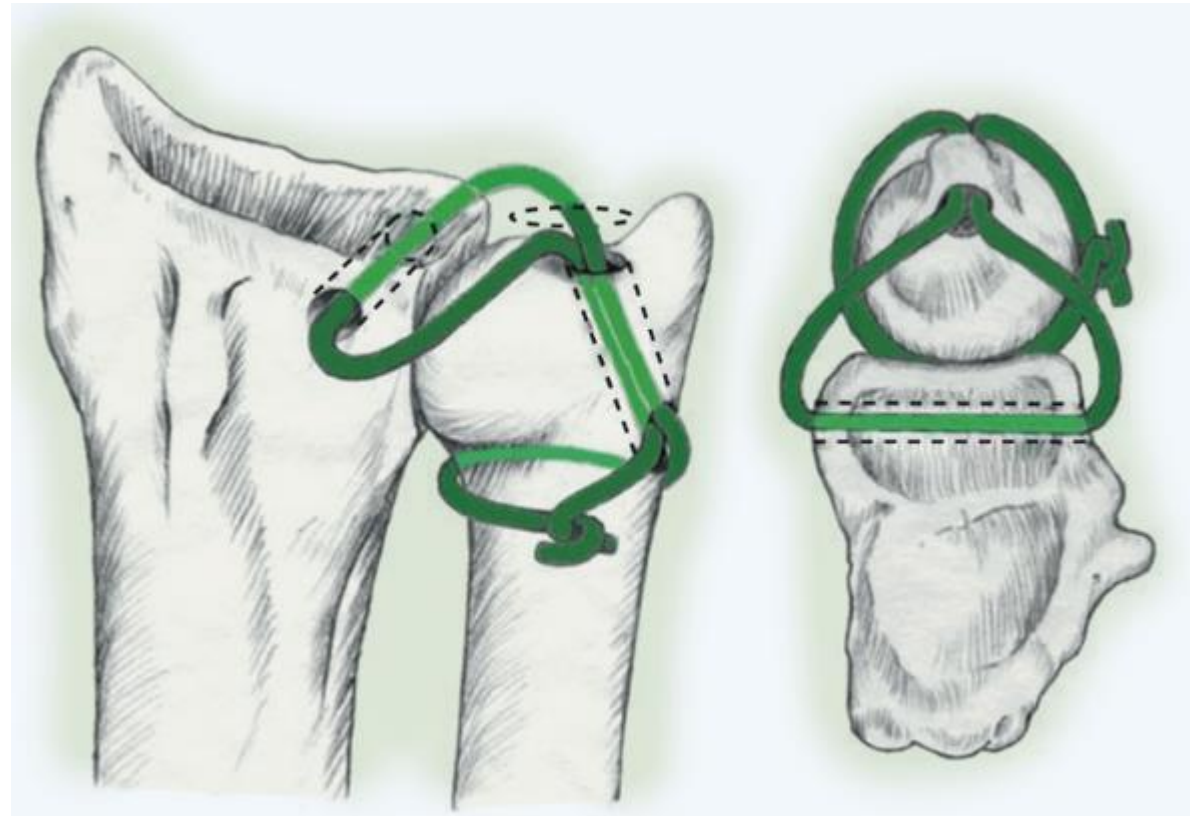
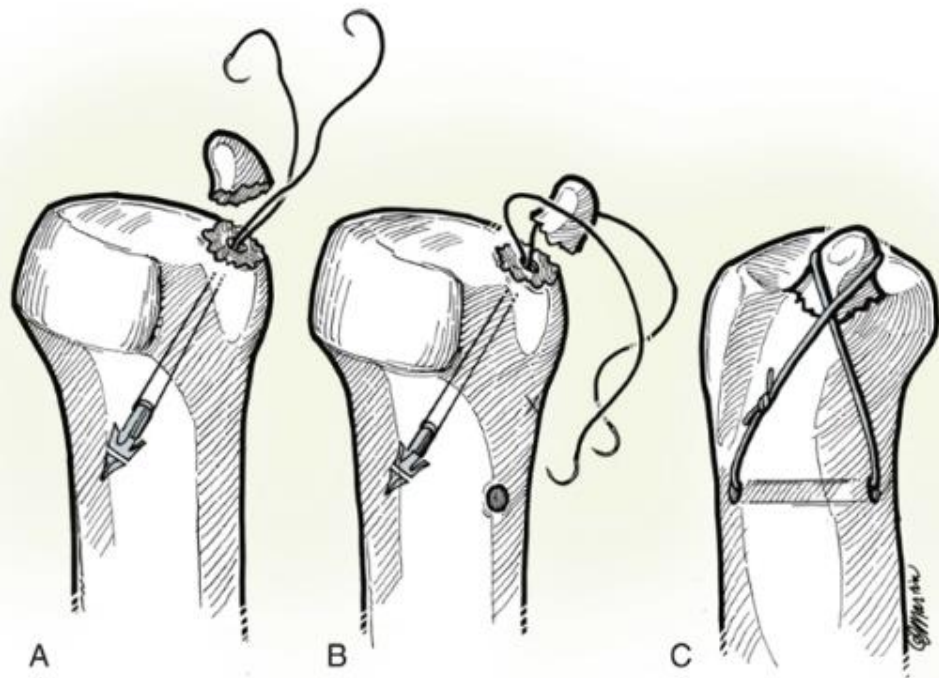
- **Piano key sign**
 - Instability



Provocative Manoeuvres - DRUJ

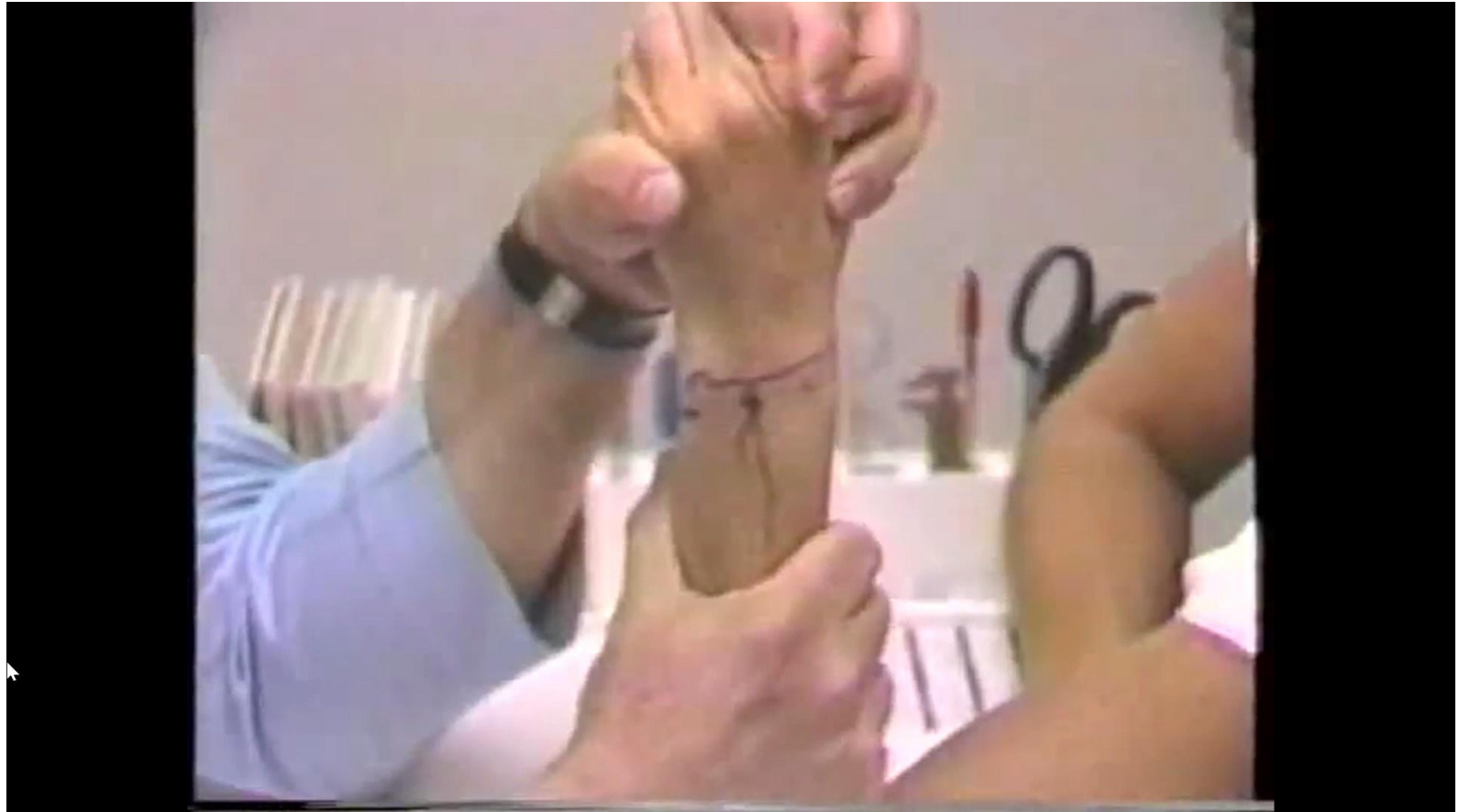- Piano key sign
- **Shuck Test**
 - Instability (TFCC)

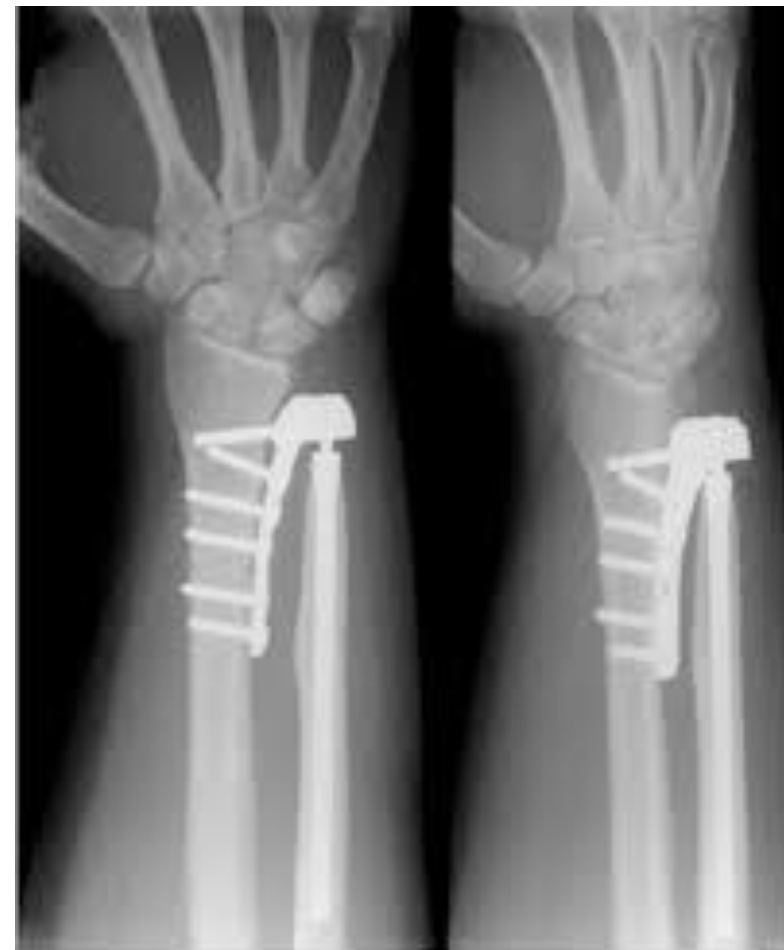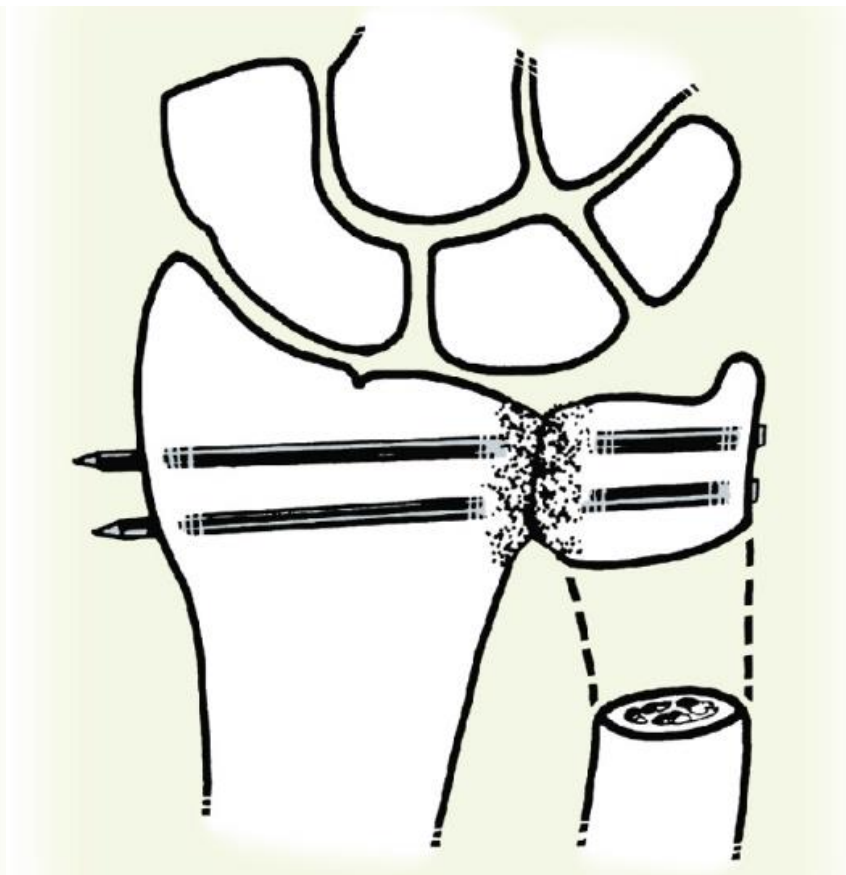
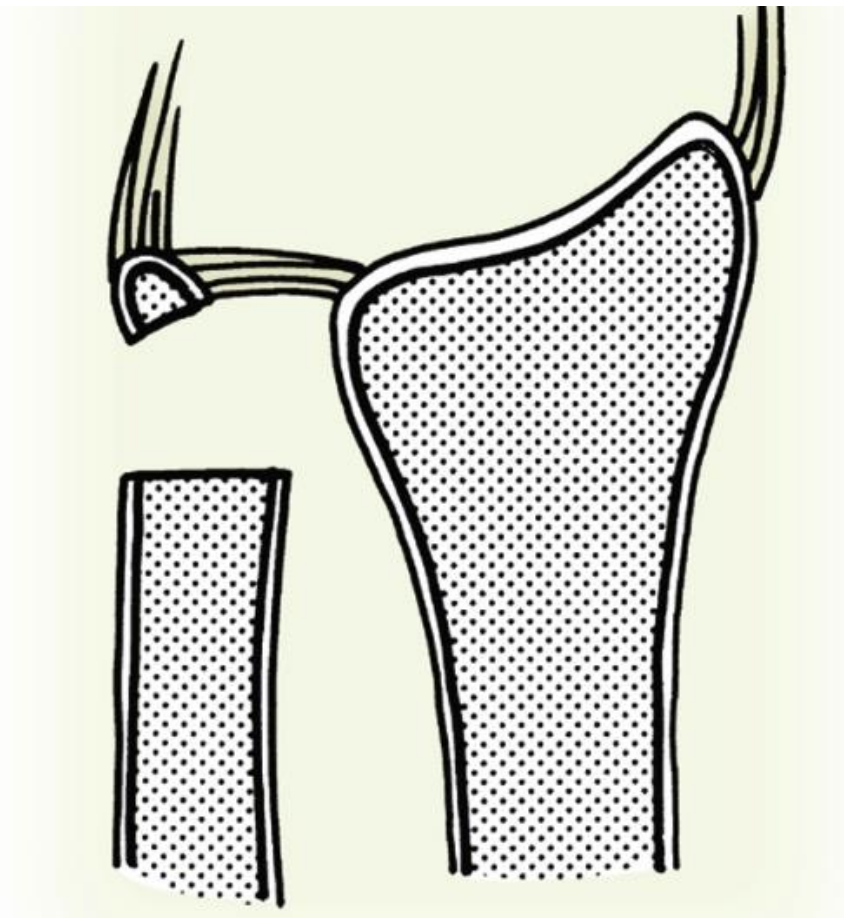




Provocative Manoeuvres - DRUJ

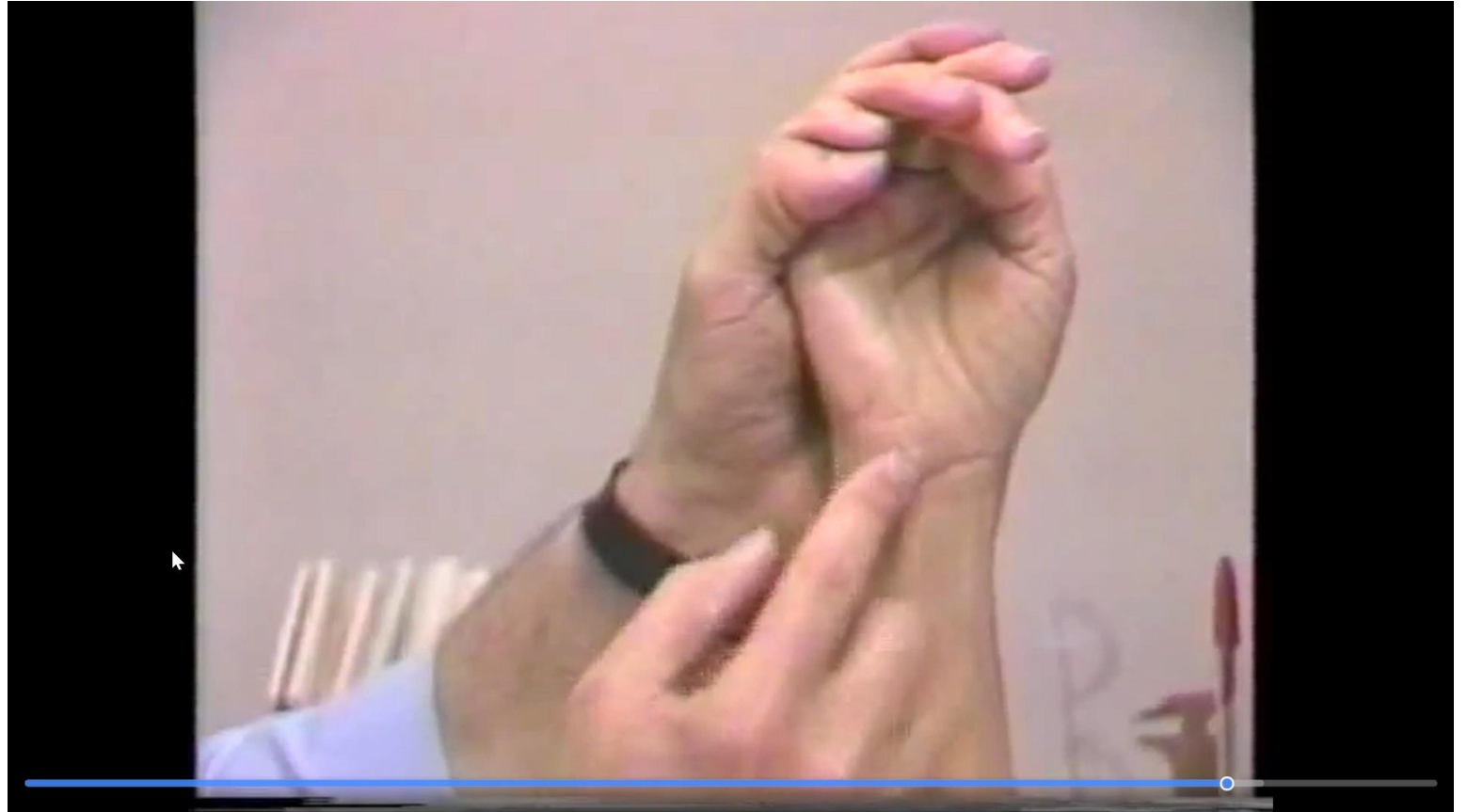- DRUJ
 - Piano key sign
 - Shuck
 - **Grind test**
 - OA

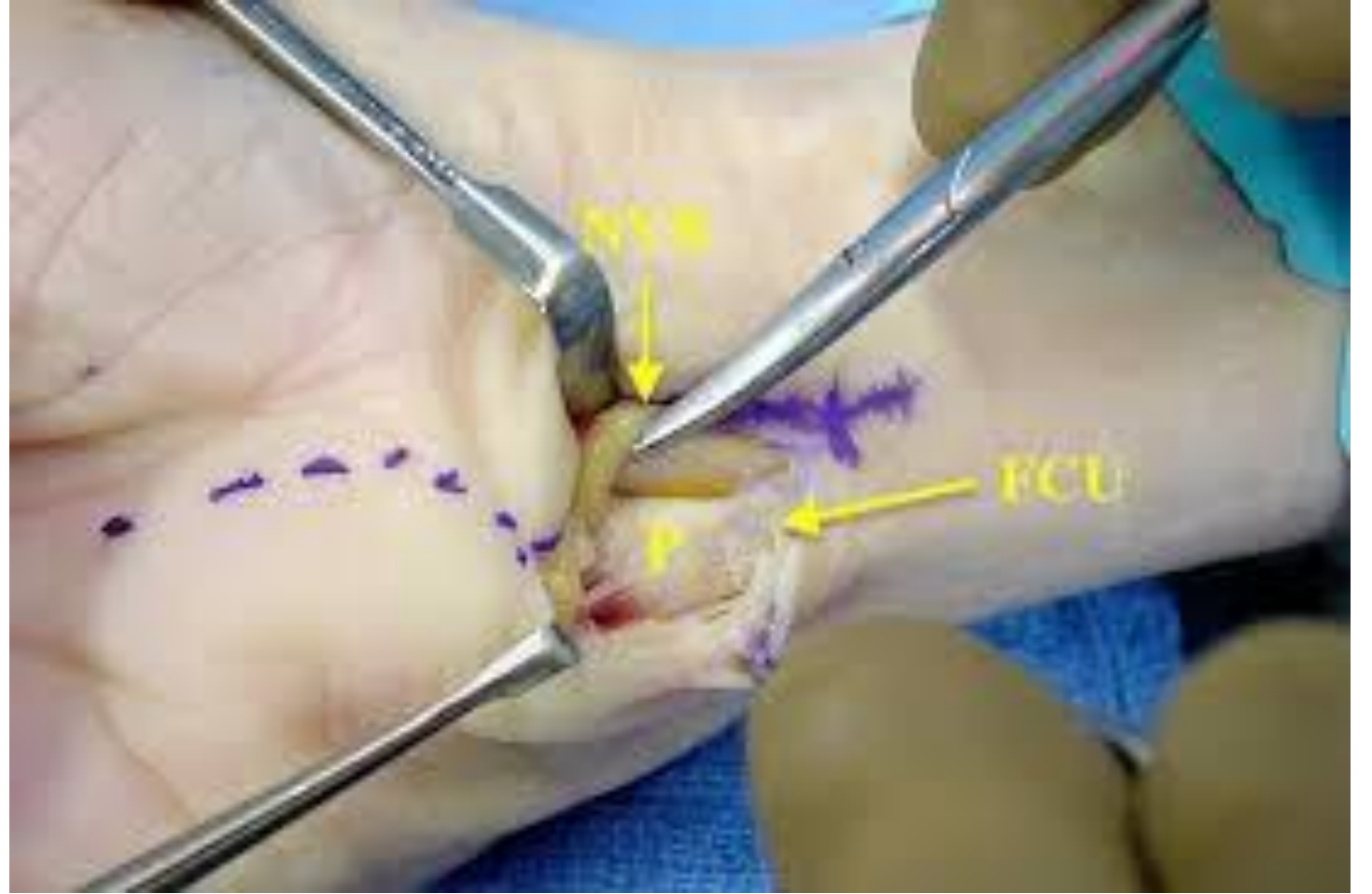
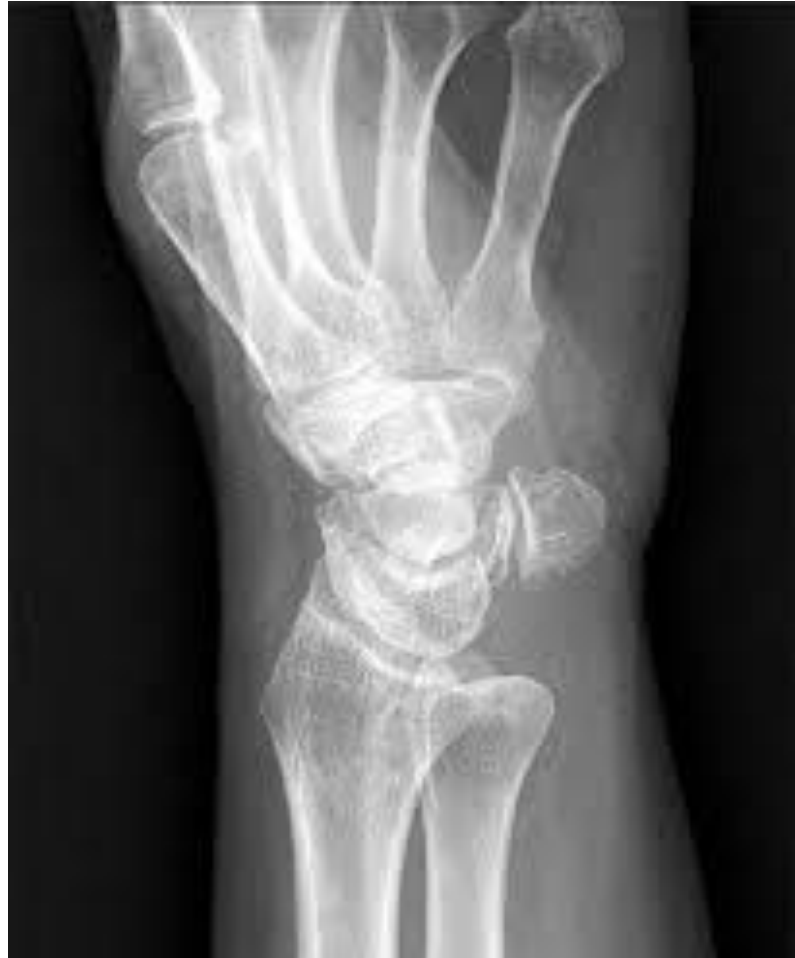



Pisotriquetral OA

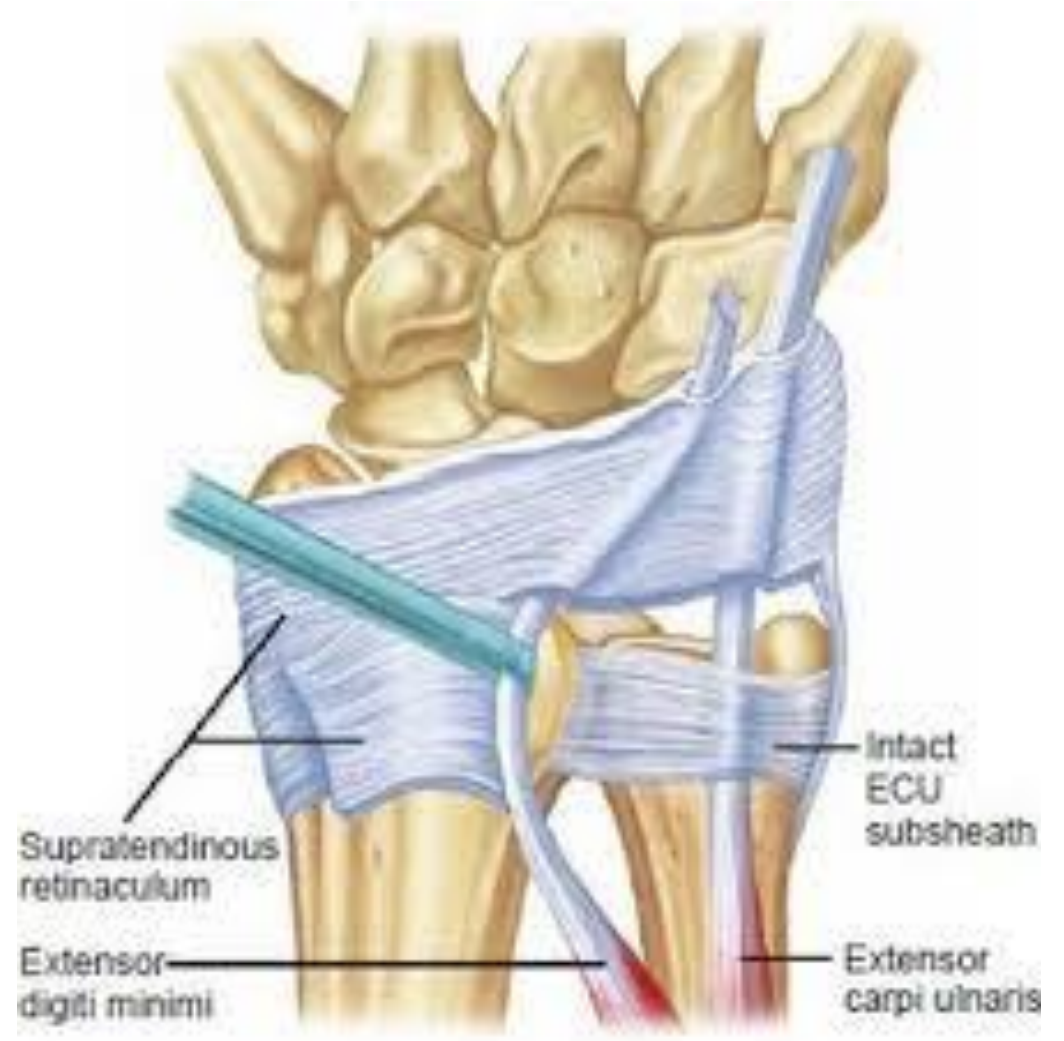- **Shear test**

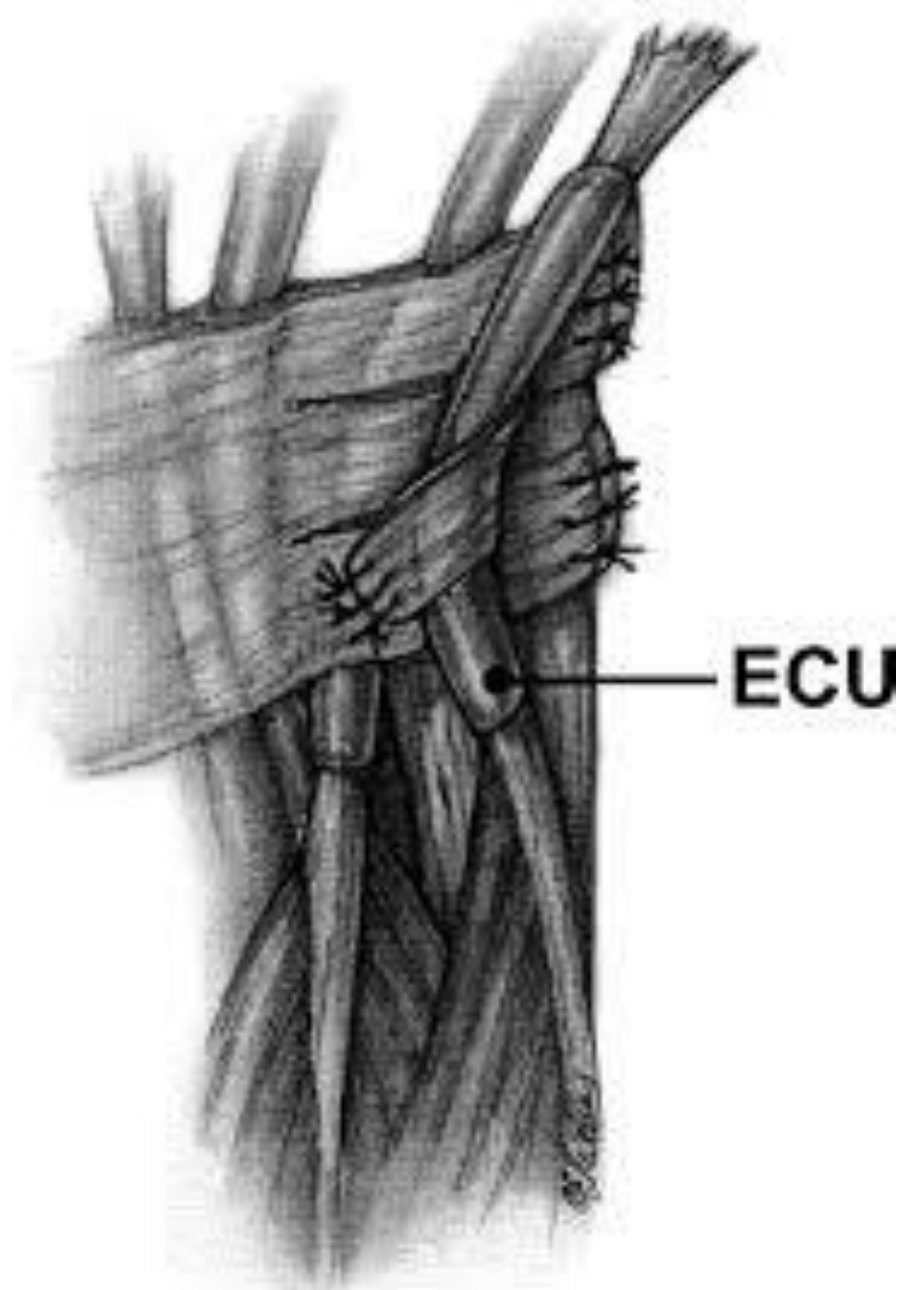




Provocative Manoeuvres - ECU

- High tens
- Ice-cream scoop
- Cobra

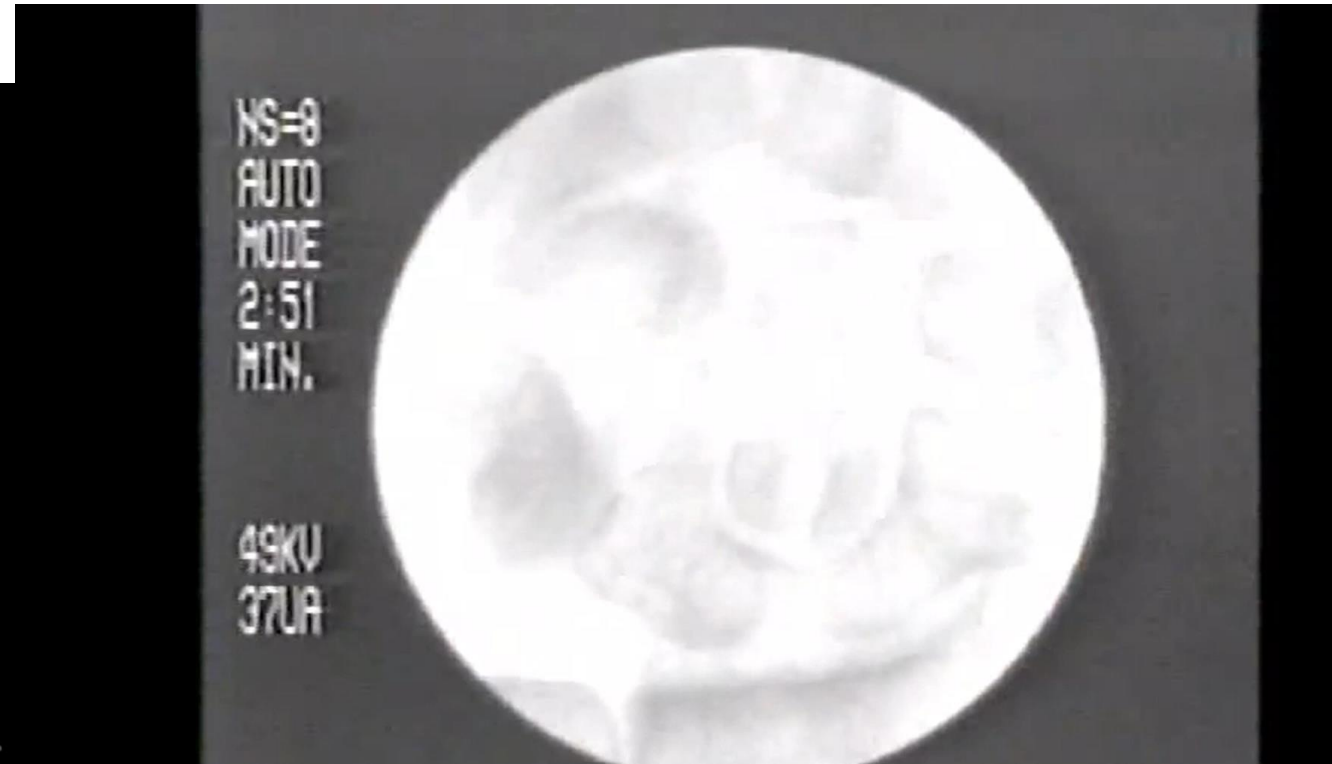
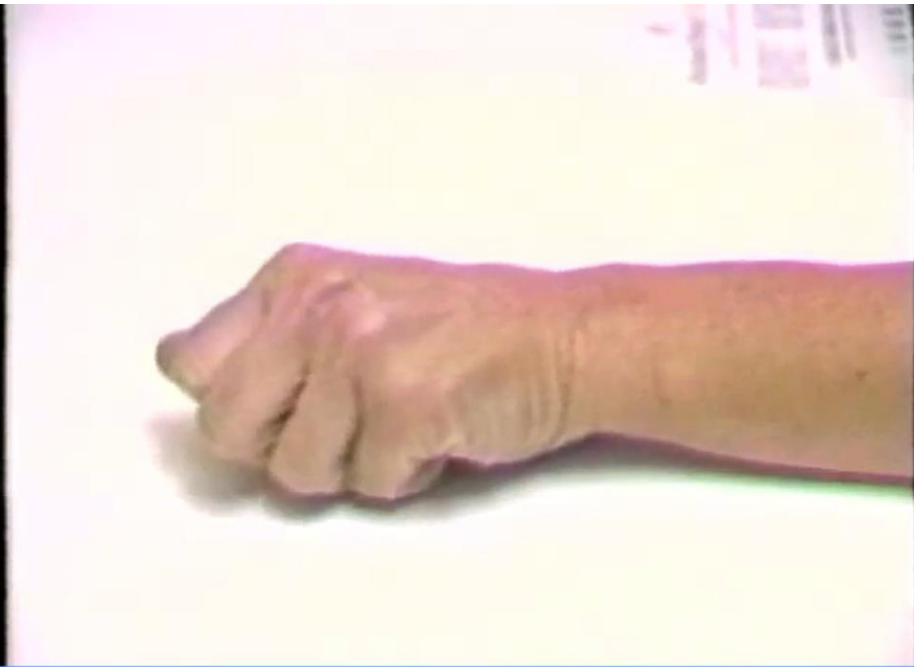




ECU

Provocative Manoeuvres – Midcarpal Instability

- Catch-up Clunk



Summary

- A sound topographical appreciation of the wrist permits accurate clinical diagnoses
- Accurate clinical diagnosis is key to successful treatment
- Palpate every key structure everytime!

Radial	Central	Ulnar
Intersection syndrome	Kienbocks	LTIL
De Quervains	Carpal Boss	TFCC
Scaphoid waist	CMC synovitis	DRUJ
STT		ECU
CMC1		
Scaphoid prox pole		
SLIL		
Occult ganglia		

Questions?



Michael@michaeelvey.com



@Elveymichael



Michaeelvey.com



07947465647

MICHAEL ELVEY
CONSULTANT ORTHOPAEDIC SURGEON
HAND, WRIST & ELBOW SPECIALIST



Neurovascular Examination

- Vascular
 - Allen's Test

- Neuro
 - 2PD
 - Phalens
 - Wartenbergs sign
 - Froments sign
 - OK sign

Hand

- Boutnonniere
- Swan-neck
- Mallet Deformity
- Intrinsic tightness
- Lunmbrical plus
- Quadriga effect